



HAL
open science

SMO mutation status defines a distinct and frequent molecular subgroup in olfactory groove meningiomas

Julien Boetto, Franck Bielle, Marc Sanson, Matthieu Peyre, Michel Kalamarides

► To cite this version:

Julien Boetto, Franck Bielle, Marc Sanson, Matthieu Peyre, Michel Kalamarides. SMO mutation status defines a distinct and frequent molecular subgroup in olfactory groove meningiomas. *Neuro-Oncology*, 2017, 19 (3), pp.now276. 10.1093/neuonc/now276 . hal-04403759

HAL Id: hal-04403759

<https://hal.sorbonne-universite.fr/hal-04403759>

Submitted on 18 Jan 2024

HAL is a multi-disciplinary open access archive for the deposit and dissemination of scientific research documents, whether they are published or not. The documents may come from teaching and research institutions in France or abroad, or from public or private research centers.

L'archive ouverte pluridisciplinaire **HAL**, est destinée au dépôt et à la diffusion de documents scientifiques de niveau recherche, publiés ou non, émanant des établissements d'enseignement et de recherche français ou étrangers, des laboratoires publics ou privés.

SMO mutation status defines a distinct and frequent molecular subgroup in olfactory groove meningiomas

Julien Boetto, Franck Bielle, Marc Sanson, Matthieu Peyre, and Michel Kalamarides

INSERM U1127, Paris, France (J.B., F.B., M.S., M.P., M.K.); Department of Neuropathology, APHP, Hôpital de La Pitié-Salpêtrière, Paris, France (F.B.); Department of Neurology, APHP, Hôpital de La Pitié-Salpêtrière, Paris, France (M.S.); Department of Neurosurgery, APHP, Hôpital de La Pitié-Salpêtrière, Paris, France (M.P., M.K.); Sorbonne Universités, UPMC, Paris, France (F.B., M.S., M.P., M.K.); Onconeurothèque, Paris, France (F.B., M.S.)

Corresponding Author: Michel Kalamarides, MD, PhD, Department of Neurosurgery, Hôpital de la Pitié Salpêtrière, 47–83 Bd de l'Hôpital, 75013 Paris, France (michel.kalamarides@aphp.fr).

Abstract

Background. Meningiomas are the most common primary intracranial tumors in adults. Identification of *SMO* and *AKT1* mutations in meningiomas has raised the hope for targeted therapies. It would be useful to know the precise frequency of these mutations in anatomical subgroups and clarify their prognostic value.

Methods. We used the Sanger sequencing technique to characterize 79 samples of olfactory groove meningiomas for *SMO* (L412F and W535L) and *AKT1E17K* mutations. We reviewed clinical data to assess the prognostic value of these mutations in this anatomical subgroup.

Results. Out of the 79 patients with olfactory groove meningiomas, we identified targetable mutations in 34 patients (43%) (22 patients [28%] with *SMO* mutation—L412F almost exclusively—and 12 patients [15%] with *AKT1* mutation). Meningiomas in the *SMO*-mutant group had an overall 36% recurrence rate, significantly higher than in the *AKT1*-mutant group (16%) and in the “*SMO* and *AKT1* wildtype” group (11%) (χ^2 test, $P = .04$). All late recurrences (after 5 y) occurred in the *SMO*-mutant group. Among grade I meningiomas, the *SMO*-mutant group was identified as having a significantly poorer prognosis. World Health Organization histological grade II ($P = .006$) and incomplete resection ($P = .001$) were independently associated with shorter recurrence-free survival.

Conclusion. Molecular diagnosis of *SMO*^{L412F/W535L} and *AKT1E17K* mutations improves prognostic evaluation in olfactory groove meningiomas and opens new therapeutic perspectives with *SMO* or *AKT* inhibitors for recurrent cases.

Key words

AKT | meningioma | molecular pathology | olfactory groove meningioma | *SMO*

Meningiomas are the most common primary brain tumors in adults.¹ Olfactory groove meningiomas (OGM) represent 4% to 13% of all intracranial meningiomas² and originate from the meningeal cells covering the lamina cribrosa and the planum sphenoidale. Their extent can damage frontal lobes and olfactory and visual functions.

Despite excellent tumor control in most cases after surgery,^{2,3} recurrence occurs in 5% to 30% according to follow-up (FU) duration.^{4–6} Prognostic factors identified in OGM are age, World Health Organization (WHO) grade, and extent of resection.^{4,7}

Removal of large or invasive tumors may be associated with significant visual and cognitive morbidity, particularly at relapse.⁸ At recurrence, treatment options include follow-up if the tumor growth is minimal, total resection if feasible, or radiosurgery/therapy.^{8,9} In rare cases, refractory meningiomas can invade the anterior skull base and/or paranasal sinuses with severe visual impairment and can be life threatening. To date, medical therapies have been largely ineffective in those cases.¹⁰

Biallelic inactivation of *NF2* is the most frequent genetic event in meningioma tumorigenesis.^{11–13} However, anterior

Importance of the study

We analyzed a large series of olfactory groove meningiomas for *SMO* and *AKT1* mutations, 2 targetable missense mutations previously described in meningiomas. We identified a *SMO* mutation (L412F or W535L) in 28% and an *AKT1*^{E17K} mutation in 15% of our cases. The high frequency of *SMO* mutations in meningiomas arising from the anterior and medial skull base might be explained by the central role of the sonic

hedgehog pathway in craniofacial development during embryogenesis. In addition, time-to-recurrence analysis shows that among grade I skull base meningiomas, the group with *SMO* mutations had a significantly poorer prognosis. Our study strongly supports the systematic screening of these prognostic markers and potentially actionable targets in skull base meningioma.

skull base topography is strongly associated with intact *NF2* gene status and meningotheial histological subtype.^{14,15}

Recently, driver mutations in *TRAF7*, *KLF4*, *PI3KCA*, *POLR2A*, *AKT1*, and *SMO* genes have been identified in non-*NF2*-mutant meningiomas.^{14,16–18} All *AKT1*-mutant meningiomas (12% of all meningiomas) harbored the same activating mutation (E17K) and were associated with lesions of low malignancy potential located at the anterior or middle skull base.^{19–21} The *SMO*-mutant meningiomas described in the literature (with a frequency between 3% and 5% of all meningiomas) showed 2 recurrent variants (L412F [70%] and W535L [15%]) and a highly recurrent phenotype of grade I meningotheial lesions arising from the anterior medial skull base.^{16,20} Interestingly, therapies are available specifically targeted against these 2 oncogenic drivers: a multicenter phase II study of vismodegib and afuresertib is under way for patients with progressive or recurrent *SMO*- and *AKT1*-mutant meningiomas, respectively (NCT02523014, clinicaltrials.gov).

Here, we report the first molecular analysis of *SMO* and *AKT1* mutations in a large OGM series, with particular emphasis on prognosis and recurrence rate.

Patients and Methods

Patient and Tissue Samples

Collection of patient samples and clinico-pathological information was undertaken with patient informed consent and hospital ethical board approval. We requested the following data from our Brain Tumor Bank (Onconeurothèque): histological diagnosis of meningioma and surgery between 2003 and 2012. We reviewed the following parameters for all patients: sex, age, Karnofsky performance scale (KPS), presenting symptoms, radiological features, extent of surgical resection and complications, treatment modalities (number of surgical procedures, need for radiotherapy or radiosurgery), and recurrence (site, time to recurrence). Exact topography on MRI and radiological features were centrally reviewed to ensure that “olfactory groove” topography was present (ie, lamina cribrosa and planum sphenoidale). The extent of resection was determined according to the Simpson grade system.²² A central pathology review was carried out by our senior pathologist (F.B.) in order to validate histological features (subtype and grading according to WHO 2016 classification, Ki67 proliferation index).

Follow-up

Patients were followed up with clinical examination and MRI at 6 months and 1 year after surgery. Then they were followed regularly every 1 to 2 years. Tumor recurrence was defined as an increase in residual tumor or the reappearance of onsite lesions on FU imaging (MRI in all cases).

Molecular Characterization

DNA extraction

DNA was extracted from fresh-frozen tumors using the QIAmp DNA minikit (Qiagen) and quantified using Nanodrop (Thermo Fischer Scientific).

Sanger sequencing

Sequencing for *SMO* was restricted to recurrent L412F and W535L mutations, with primers as follows: *SMO*^{L412F}_F: AGTGACTGGTAGGAACGGGAG; *SMO*^{L412F}_R: GGAGCTAGCTGGGGTTTCAG; *SMO*^{W535L}_F: CCCATCCCTGACTGTGAGAT; *SMO*^{W535L}_R: CAGGTACGCCTCCAGATGAG.

Fragments spanning codon 17 of *AKT1* were amplified using the following primers: *AKT1*^{E17K}_F: AAGACTCGGCAGCATCTCCAGCAGGCATCCCAGGCACA TCTGTCCA^{AKT1}^{E17K}_R: GCGATCGTCACTGTTCTCAGTAGCGTGGCCGCCAGGTTGATGACT.

PCR was carried out with a total volume of 10 μ L containing 50 ng template DNA in Fast Start PCR Master Mix (Roche). Initial denaturation at 94°C for 10 min was followed by 30 cycles with denaturation at 94°C for 30 s, annealing at 55°C for 30 s, and extension at 72°C for 1 min, followed by 10 min at 72°C. Then, 3 μ L of amplification product was submitted to sequencing (Genoscreen). Sequences were read with 4Peaks software (Macintosh).

Statistical Analysis

The χ^2 test (with Yates correction when appropriate) and the Kruskal–Wallis test were used to compare the distributions of categorical and continuous variables, respectively. Progression-free survival (PFS) was defined as the time between surgery and recurrence or last FU. Patients who were recurrence free at last FU were considered to be censored in analysis. Kaplan–Meier survival curves were plotted, and differences in survival between groups of patients

were compared with the log-rank (Mantel–Cox) test. The influence of age (<70 vs ≥70 y), Simpson grade (I–II vs III–IV), WHO histological grade (I vs II), and mutational status on *SMO* and *AKT1* genes in recurrence-free survival were assessed. Multivariate analysis was then performed with the Cox proportional hazards model incorporating the major prognostic factors of univariate analysis. All statistical tests were 2-sided and a *P*-value of ≤.05 was considered to be statistically significant. Statistical analyses were performed using Statview version 5.0 software (SAS Institute).

Results

Patient Population

Among the 1439 frozen meningioma samples available in Onconeurothèque, 260 were described as “anterior skull base” meningiomas (orbital, olfactory groove [including lamina cribrosa and planum sphenoidale], tuberculum sellae, anterior clinoid process, or suprasellar meningiomas). Among them, 79 were confirmed as olfactory groove tumors based on surgical and radiological data and were included in our study: the main demographic characteristics are summarized in Table 1. There were 62 females (79%) and 17 males (21%). Median preoperative KPS was 90 (range, 40–100); 76 patients were operated on for a primary tumor, and 3 for a recurrent tumor (data from the first surgery [pathology, Simpson grade, and PFS] were considered for these patients). Median FU was 70 months (range, 2–312). One patient died of a pulmonary embolism after surgery, and 5 patients (6.3%) had no reliable

postoperative FU (one in the *SMO* group and 4 in the “others” group with neither *SMO* nor *AKT1* mutation). Survival analysis was thus conducted on 73 patients who had at least one postoperative examination and imaging available.

Molecular Subgroups

Of the 79 OGM, 22 (28%) carried a *SMO* mutation: 21 with L412F and 1 with W535L. Twelve (15%) presented an *AKT1*^{E17K} mutation (Fig. 1). *SMO* and *AKT1*^{E17K} mutations were mutually exclusive and no tumor had both mutations. The remaining 45 meningiomas were defined as “others” in a third group with neither *SMO* nor *AKT1* mutation. Only one patient had a molecular analysis of a primary and a recurrent frozen meningioma that both contained *SMO* mutations.

Demographic, Clinical, and Perioperative Data

Demographic, clinical, and imaging findings in the 3 groups (*SMO*-mutant, *AKT1*-mutant, and “others”) are summarized in Table 1. There was no difference in demographic features among the 3 molecular subgroups. Presenting symptoms were similar in all groups, apart from anosmia, which was significantly more common in the *SMO*-mutant group (*P* = .01).

No significant difference was found in tumor size among the 3 groups. Peritumoral frontal edema on fluid attenuated inversion recovery–weighted sequences was present in all cases. Clinical and demographic findings from the general cohort were consistent with published OGM cohorts.^{2,4,5} Simpson grades I–II resection was achieved in 91%, 75%,

Table 1 Clinical and imaging data

Demographic Data	General Cohort (n = 79)	<i>SMO</i> (n = 22)	<i>AKT1</i> (n = 12)	Others (n = 45)	<i>P</i>
Sex					
Male	17 (21%)	4 (18%)	2 (16%)	11 (25%)	.76
Female	62 (79%)	18 (82%)	10 (84%)	34 (75%)	
Age, y					
Median	55	55	56	55	.94
Range	22–83	22–72	30–75	26–83	
Median preoperative KPS	90	90	80	90	.95
Median FU (mo)	70	83	60	72	.18
Presenting symptoms					
Headache	46 (58%)	12 (54%)	6 (50%)	28 (62%)	.68
Visual impairment	33 (41%)	13 (59%)	3 (25%)	17 (38%)	.11
Anosmia	56 (71%)	20 (91%)	7 (58%)	29 (64%)	.04
Cognitive impairment	38 (48%)	13 (59%)	5 (42%)	20 (45%)	.47
Seizures	4 (5%)	2 (9%)	1 (8%)	1 (2%)	.41
Imaging data					
Size					
Mean tumor diameter (mm)	59	63	54	51	.28
Range	30–90	35–80	30–90	30–70	
Hyperostotic bone	52 (66%)	17 (77%)	6 (50%)	29 (65%)	.26

and 88% of the *SMO*, *AKT1*, and “others” groups, respectively ($P = .36$) (Table 2).

Comparative Analysis of Histological Features and Molecular Subgroups

The *SMO*-mutant meningiomas showed a uniform histological phenotype: all were WHO grade I and meningothelial, with low Ki67 index and 1 or less mitosis per 10 high-power fields. The *AKT1*-mutant meningiomas were more heterogeneous: 8 (67%) were grade I (all meningothelial) and 4 (33%) were grade II (one chordoid and 3 atypical). Other histological features are summarized in Table 3.

Impact of Molecular Characterization on Natural Course and Recurrence Rates

The main treatment modalities (surgery and radiotherapy; no patient was treated with systemic therapy) and recurrence rates are shown in Table 2. Meningiomas in the *SMO*-mutant group had an overall 36% recurrence rate, significantly higher than in the *AKT1*-mutant group (16%) and the “others” group (*AKT1*-wildtype, *SMO*-wildtype) (11%) ($P = .04$). Despite the fact that the 5-year PFS rate was similar in the 3 groups (81%, 83%, and 82%), the 10-year PFS rate was lower in the *SMO*-mutant group (52%) than in the *AKT1*-mutant (83%) and “others” groups (82%) ($P = .008$).

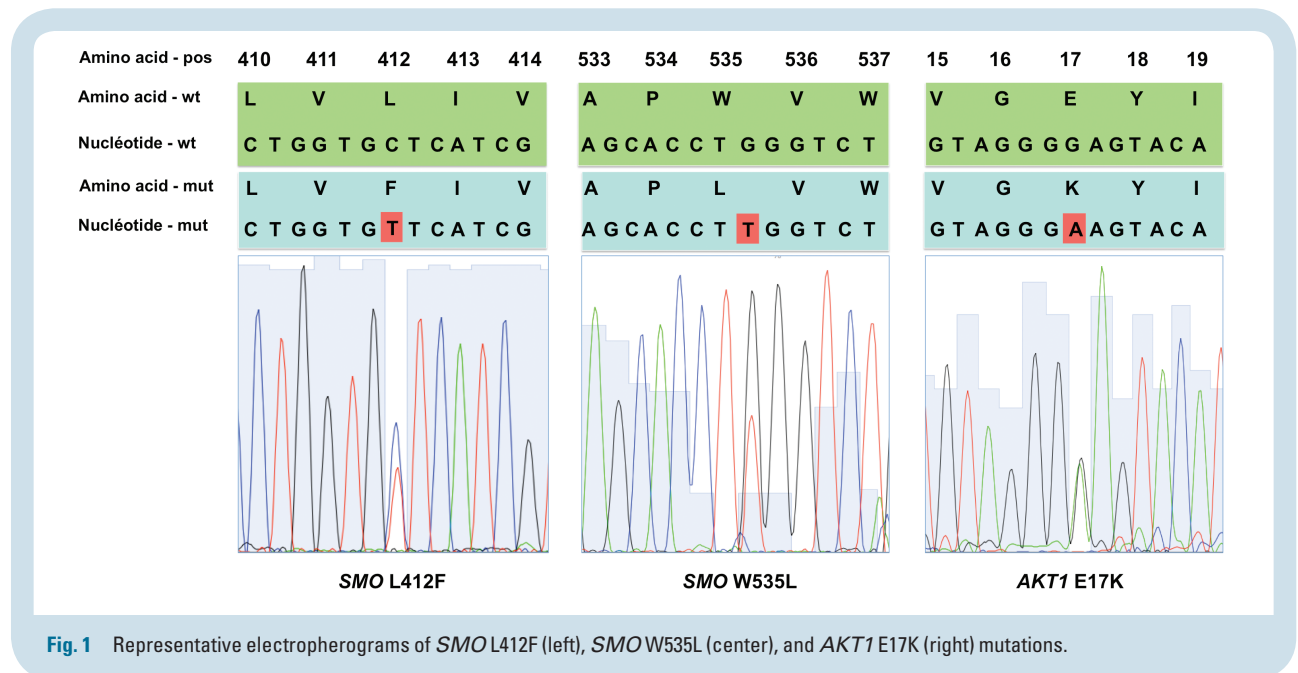


Fig. 1 Representative electropherograms of *SMO* L412F (left), *SMO* W535L (center), and *AKT1* E17K (right) mutations.

Table 2 Treatment modalities and recurrence rates

Treatment Modalities	General Cohort	<i>SMO</i>	<i>AKT1</i>	Others	<i>P</i>
Recurrence Rates					
Simpson grade					
I-II	69 (87%)	20 (91%)	9 (75%)	40 (88%)	.36
III-IV	10 (13%)	2 (9%)	3 (25%)	5 (12%)	
N surgery(ies)					
1	72 (91%)	18 (81%)	11 (91%)	43 (96%)	.17
2	5 (6%)	3 (15%)	1 (9%)	1 (2%)	
≥3	2 (3%)	1 (4%)	0 (0%)	1 (2%)	
Radiotherapy/radiosurgery	3 (4%)	2 (9%)	1 (8%)	0	.22
Recurrence rate	13 (16%)	8 (36%)	2 (16%)	5 (11%)	.04
5 y PFS	81%	81%	83%	82%	.93
10 y PFS	65%	52%	83%	82%	.008
Median PFS (mo)	65	79	53	63	.65

WHO grade II ($P < .0001$, Fig. 2A) and Simpson grade III or IV resection ($P < .0001$, Fig. 2B) were associated with poor survival, but no significant differences were observed according to the 3 molecular groups ($P = .32$) (Fig. 2C), or age (<70 vs ≥ 70 y) ($P = .33$). When focusing the analysis on

grade I OGM ($n = 62$), we observed that the *SMO*-mutant group had a significantly poorer prognosis ($P = .007$) (Fig. 2D). On multivariate analysis, WHO histological grade II ($P = .006$) and incomplete resection ($P = .001$) were independently associated with shorter recurrence-free survival,

Table 3 Histological features

Pathology	General	<i>SMO</i>	<i>AKT1</i>	Others	<i>P</i>
Grade					
I	69 (89%)	22 (100%)	8 (67%)	39 (89%)	.14
II	9 (11%)	0 (0%)	4 (33%)	5 (11%)	
Ki 67					
Mean	4	3.55	4.18	4.45	.22
Range	1–8	1–6	3–6	1–8	
Histological subtype					
Meningothelial	55 (69%)	22 (100%)	8 (67%)	25 (55%)	.0004
Fibroblastic	4 (5%)	0	0	4 (9%)	
Transitional	7 (9%)	0	0	7 (15%)	
Psammomatous	2 (3%)	0	0	2 (4%)	
Microcystic	1 (1%)	0	0	1 (2%)	
Atypical	9 (11%)	0	3 (25%)	6 (13%)	
Chordoid	1 (1%)	0	1 (8%)	0	

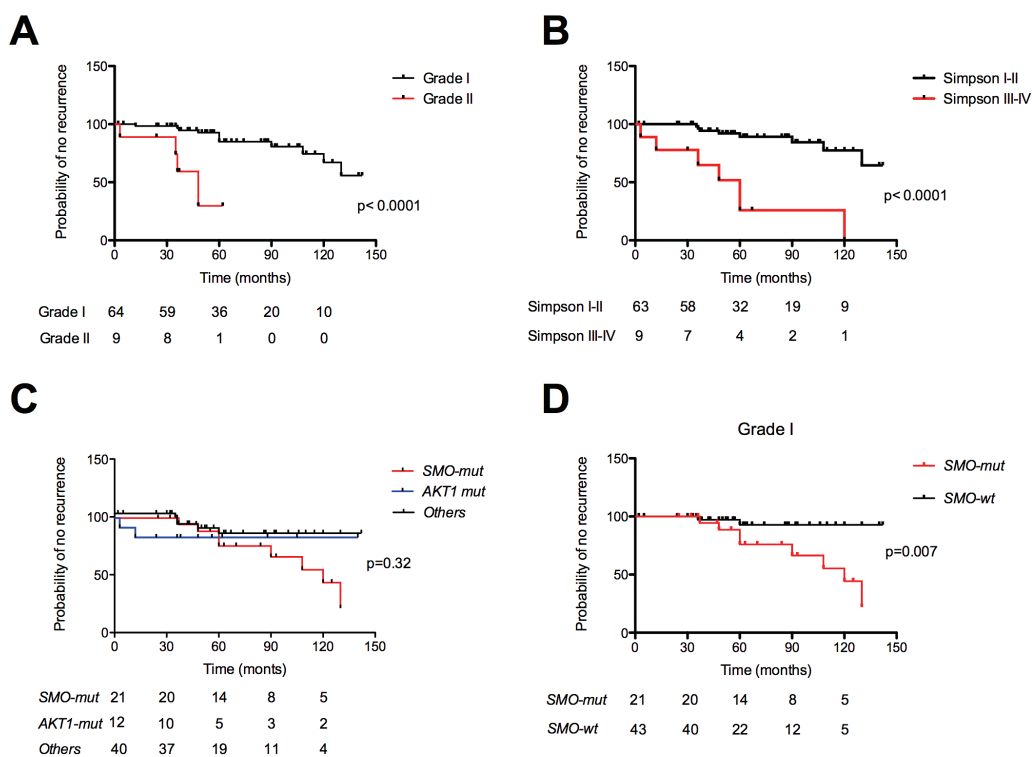


Fig. 2 Kaplan–Meier plots of time to recurrence, according to (A) WHO grade (grade I vs grade II, $P < .0001$); (B) extent of resection (Simpson I–II vs Simpson III–IV, $P < .0001$); (C) molecular subgroups for the whole cohort (*SMO*-mutant [*SMO*-mut], *AKT1*-mutant [*AKT1*-mut] and “others” meningiomas [$P = .32$, NS]), and (D) for grade I only: *SMO*-mutants have a poorer prognosis than *SMO*-wt ($P = .008$). wt = wildtype.

whereas *SMO*-mutation did not reach statistical significance ($P = .06$).

When reviewing the patterns of relapse of OGM, we identified 4 cases (5%) of surgery- and radiation-refractory meningiomas with nasal fossa and paranasal sinus invasion associated with severe visual impairment and pituitary dysfunction. Three of them carried targetable mutations (2 had *SMO*^{L412F}, and 1 had the *AKT1* mutation) (Fig. 3).

Discussion

We focused the analysis of this large OGM series on 2 frequent and potentially actionable mutations. Indeed, specific *SMO* and *AKT1* inhibitors are under evaluation and will certainly provide new therapeutic options in the near future. This is not the case for *NF2* mutations (rarely mutated in anterior skull base meningothelial meningiomas), *KLF4* mutations (specific for secretory meningioma, absent in this cohort), and *TRAF7* mutations. We identified a targetable mutation in almost half of tumors (43%). *SMO* (L412F or W535L) mutations were found in 28% of OGM, much more frequently than in meningiomas in any other location (3% to 5%),^{14,17,18} confirming its association with a specific topography and histology (grade I, meningothelial subtype). *SMO* is a 7-transmembrane domain protein belonging to the sonic hedgehog (SHH) pathway that plays a key role in embryogenesis and is implicated in several cellular processes, including proliferation, differentiation, and angiogenesis.²³ The strong association of the *SMO* mutation with anterior skull base location is probably related to the central role of the SHH pathway in the development of the ventral forebrain and median craniofacial skeleton.^{24,25} Our results concerning histological characterization of *SMO*-mutant meningioma as meningothelial grade I lesions in all cases are in line with the findings summarized in a recent review of published cases of *SMO*-mutant meningiomas.²⁰

AKT1^{E17K} was mutated in 15% of OGM, which is similar to the 12% found in non-*NF2* meningiomas in any location.^{14,19} We confirmed that the olfactory groove is not particularly associated with the *AKT1* mutation, in line with previous

reports on *AKT1*-mutant meningiomas of the anterior clinoid process, tuberculum sellae, clivus, sphenoid wing, or spine.^{14,17,18} If most *AKT1*-mutant meningiomas were grade I and meningothelial (67%), they showed a more heterogeneous profile with regard to histological subtype (atypical, chordoid) as published in the literature.¹⁹⁻²¹

Apart from WHO grade II and incomplete resections which were associated with shorter PFS as expected,⁷ we also observed that the *SMO*-mutant meningiomas had an overall recurrence rate higher than the *AKT*-mutant or "others" group. Moreover, all patients who experienced late recurrence (after 5 y) had a *SMO*-mutant meningioma, and these were exclusively grade I meningiomas. On multivariate analysis, the prognostic value of molecular characterization did not reach statistical significance, making further studies with a large cohort mandatory to confirm our results. Yuzawa and colleagues recently reported a 6% recurrence rate for *SMO*-mutant meningiomas, but data were only available for 8 patients, and length of FU was not mentioned.^{20,21} As the WHO 2016 classifications introduced the use of integrated histological and genotypic parameters to define more focused histomolecular diagnostic entities, such molecular information should also help guide and improve the current classification and therapeutic management of meningiomas. The prognostic value of *AKT1* mutations in OGM is less clear, and our results in this subgroup must be taken with caution because of the small number of cases: 4 patients with grade II and 2 patients with incomplete resections at recurrence. Additional studies with larger cohorts and other anatomical topographies are needed to assess the specific prognostic value of *AKT1* mutations in skull base meningiomas.

Based on our results, we recommend a simple molecular analysis of OGM (with at least *SMO*^{L412F} and *AKT1*^{E17K} mutation status) after initial surgery to define more precisely the prognosis and extend FU for *SMO*-mutant meningiomas. In our OGM series, we have identified at least 3 cases that had unfavorable outcomes and for whom efficient targeted medical therapies would have provided an invaluable therapeutic tool. Large series of skull base meningiomas with precise location information and at least *SMO* and *AKT1* mutation analysis and long-term FU with PFS analysis (as we have performed for OGM) are needed to establish new

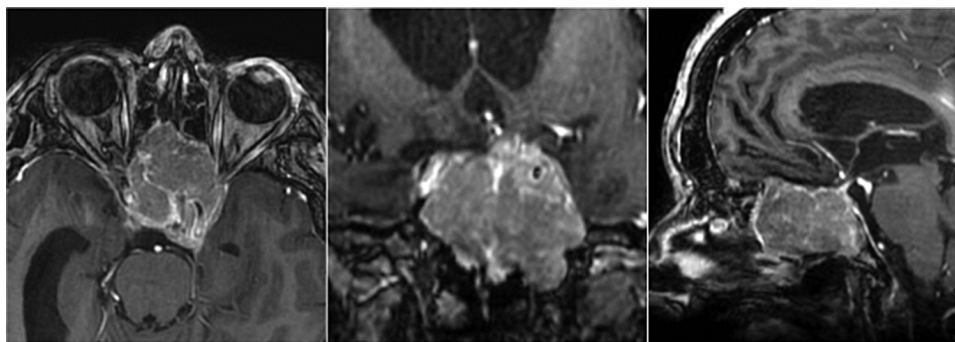


Fig. 3 Axial (left), coronal (center), and sagittal (right) T1-weighted MRI scans with gadolinium enhancement showing invasive skull base recurrence of a *SMO*-mutant olfactory groove meningioma previously operated on 3 times and treated with radiotherapy in a 45-year-old woman. Both optic canals and pituitary gland and both carotid arteries are invaded and the patient suffers from pituitary dysfunction and blindness.

treatment paradigms and FU decisions based on genetic classification as in other brain tumors.²⁶

Funding

This work was supported by a grant from the Fondation ARC (PJA 20131200431), France. J.B. was funded by a grant from UM1 University, Montpellier, France.

Acknowledgments

We are indebted to Marine Giry and Amithys Rahimian for technical assistance and Shai Rosenberg for statistical analyses.

Conflict of interest statement. The authors declare no competing financial interests.

References

- Louis DN, Ohgaki H, Wiestler OD. *WHO Classification of Tumours of the Central Nervous System. Revised*. 4th ed. Lyon: International Agency for Research on Cancer; 2016.
- Nakamura M, Struck M, Roser F, et al. Olfactory groove meningiomas: clinical outcome and recurrence rates after tumor removal through the frontolateral and bifrontal approach. *Neurosurgery*. 2007;60(5):844–852.
- Obeid F, Al-Mefty O. Recurrence of olfactory groove meningiomas. *Neurosurgery*. 2003;53(3):534–542; discussion 542–543.
- Pallini R, Fernandez E, Lauretti L, et al. Olfactory groove meningioma: report of 99 cases surgically treated at the Catholic University School of Medicine, Rome. *World Neurosurg*. 2015;83(2):219–231-3.
- Bassiouni H, Asgari S, Stolke D. Olfactory groove meningiomas: functional outcome in a series treated microsurgically. *Acta Neurochir (Wien)*. 2007;149(2):109–121; discussion 121.
- Domingues PH, Sousa P, Otero Á, et al. Proposal for a new risk stratification classification for meningioma based on patient age, WHO tumor grade, size, localization, and karyotype. *Neuro-Oncol*. 2014;16(5):735–747.
- Rogers L, Barani I, Chamberlain M, et al. Meningiomas: knowledge base, treatment outcomes, and uncertainties. A RANO review. *J Neurosurg*. 2015;122(1):4–23.
- Tomasello F, Angileri FF, Grasso G, et al. Giant olfactory groove meningiomas: extent of frontal lobes damage and long-term outcome after the pterional approach. *World Neurosurg*. 2011;76(3-4):311–317; discussion 255–258.
- Gande A, Kano H, Bowden G, et al. Gamma knife radiosurgery of olfactory groove meningiomas provides a method to preserve subjective olfactory function. *J Neurooncol*. 2014;116(3):577–583.
- Kaley T, Barani I, Chamberlain M, et al. Historical benchmarks for medical therapy trials in surgery- and radiation-refractory meningioma: a RANO review. *Neuro-Oncol*. 2014;16(6):829–840.
- Ruttledge MH, Sarrazin J, Rangaratnam S, et al. Evidence for the complete inactivation of the NF2 gene in the majority of sporadic meningiomas. *Nat Genet*. 1994;6(2):180–184.
- Bi WL, Abedalthagafi M, Horowitz P, et al. Genomic landscape of intracranial meningiomas. *J Neurosurg*. 2016;125(3):525–535.
- Domingues P, González-Tablas M, Otero Á, et al. Genetic/molecular alterations of meningiomas and the signaling pathways targeted. *Oncotarget*. 2015;6(13):10671–10688.
- Clark VE, Erson-Omay EZ, Serin A, et al. Genomic analysis of non-NF2 meningiomas reveals mutations in TRAF7, KLF4, AKT1, and SMO. *Science*. 2013;339(6123):1077–1080.
- Kros J, de Greve K, van Tilborg A, et al. NF2 status of meningiomas is associated with tumour localization and histology. *J Pathol*. 2001;194(3):367–372.
- Clark VE, Harmancı AS, Bai H, et al. Recurrent somatic mutations in POLR2A define a distinct subset of meningiomas. *Nat Genet*. August 2016;48(10):1253–1259.
- Abedalthagafi M, Bi WL, Aizer AA, et al. Oncogenic PI3K mutations are as common as AKT1 and SMO mutations in meningioma. *Neuro-Oncol*. January 2016;18(5):649–655.
- Brastianos PK, Horowitz PM, Santagata S, et al. Genomic sequencing of meningiomas identifies oncogenic SMO and AKT1 mutations. *Nat Genet*. 2013;45(3):285–289.
- Sahm F, Bissel J, Koelsche C, et al. AKT1E17K mutations cluster with meningothelial and transitional meningiomas and can be detected by SFRP1 immunohistochemistry. *Acta Neuropathol (Berl)*. 2013;126(5):757–762.
- Yuzawa S, Nishihara H, Tanaka S. Genetic landscape of meningioma. *Brain Tumor Pathol*. 2016;33(4):237–247.
- Yuzawa S, Nishihara H, Yamaguchi S, et al. Clinical impact of targeted amplicon sequencing for meningioma as a practical clinical-sequencing system. *Mod Pathol Off J U S Can Acad Pathol Inc*. 2016;29(7):708–716.
- Simpson D. The recurrence of intracranial meningiomas after surgical treatment. *J Neurol Neurosurg Psychiatry*. 1957;20(1):22–39.
- Ng JMY, Curran T. The Hedgehog's tale: developing strategies for targeting cancer. *Nat Rev Cancer*. 2011;11(7):493–501.
- Jeong J, Mao J, Tenzen T, et al. Hedgehog signaling in the neural crest cells regulates the patterning and growth of facial primordia. *Genes Dev*. 2004;18(8):937–951.
- Xavier GM, Seppala M, Barrell W, et al. Hedgehog receptor function during craniofacial development. *Dev Biol*. 2016;415(2):198–215.
- Eckel-Passow JE, Lachance DH, Molinaro AM, et al. Glioma groups based on 1p/19q, IDH, and TERT promoter mutations in tumors. *N Engl J Med*. 2015;372(26):2499–2508.