



HAL
open science

Management of tegmen defects with mastoid and epitympanic obliteration using S53P4 bioactive glass

Françoise Remangeon, Ghizlene Lahlou, Lauranne Alciato, Frederic Tankere, Isabelle Mosnier, Olivier Sterkers, Nadya Pyatigorskaya, Daniele Bernardeschi

► To cite this version:

Françoise Remangeon, Ghizlene Lahlou, Lauranne Alciato, Frederic Tankere, Isabelle Mosnier, et al.. Management of tegmen defects with mastoid and epitympanic obliteration using S53P4 bioactive glass. *Laryngoscope Investigative Otolaryngology*, 2020, 5 (2), pp.297-304. 10.1002/lio2.374 . hal-04483797

HAL Id: hal-04483797

<https://hal.sorbonne-universite.fr/hal-04483797>

Submitted on 29 Feb 2024

HAL is a multi-disciplinary open access archive for the deposit and dissemination of scientific research documents, whether they are published or not. The documents may come from teaching and research institutions in France or abroad, or from public or private research centers.

L'archive ouverte pluridisciplinaire **HAL**, est destinée au dépôt et à la diffusion de documents scientifiques de niveau recherche, publiés ou non, émanant des établissements d'enseignement et de recherche français ou étrangers, des laboratoires publics ou privés.



Distributed under a Creative Commons Attribution - NonCommercial - NoDerivatives 4.0 International License

ORIGINAL RESEARCH

Management of tegmen defects with mastoid and epitympanic obliteration using S53P4 bioactive glass

Françoise Remangeon MD¹ | Ghizlene Lahlou MD¹  | Lauranne Alciato MD¹ |
 Frederic Tankere MD, PhD¹ | Isabelle Mosnier MD¹ | Olivier Sterkers MD, PhD¹ |
 Nadya Pyatigorskaya MD, PhD² | Daniele Bernardeschi MD, PhD¹ 

¹APHP, Département d'Otologie, d'implants auditifs et de base du crâne, auditory Groupe Hospitalo-Universitaire Pitié-Salpêtrière, Paris, France

²APHP, Département de Neuroradiologie, Groupe Hospitalo-Universitaire Pitié-Salpêtrière, Paris, France

Correspondence

Daniele Bernardeschi, Otolaryngology, Auditory Implants and Skull Base Department, Pitié-Salpêtrière Hospital, 47 Boulevard de l'hôpital, 75013 Paris, France.

Email: daniele.bernardeschi@aphp.fr

Abstract

Objective: To evaluate the surgical results and complications in a cohort of patients operated on to repair a tegmen bony defect using either transmastoid approach with obliteration using S53P4 bioactive glass granules (TMA-O), or the classic middle cranial fossa approach (MCFA).

Study design: A retrospective monocentric study.

Methods: Twenty-five cases (24 patients) were included. Data regarding patient demographics, etiology, intraoperative findings, complications, recurrences, audiometric data, and follow-up were analyzed.

Results: Seven patients were operated with MCFA and 17 patients with TMA-O. One patient was operated on using a combined approach (MCFA + TMA-O). In the preoperative HRCT scan, the size of the defect was estimated to be 6 ± 3.8 mm in the TMA-O group and 6 ± 3.5 mm in the MCFA group ($P = .969$). Intraoperatively, in the MCFA group, the location of the defect was mostly anterior (86%) with an intact ossicular chain (86%). A discontinuous chain was observed in 15 patients (88%) in the TMA-O group. The mean follow-up time was 22 ± 14 months in the TMA-O group and 24 ± 15 months in the MCFA group ($P = .762$). In both groups, there were no early postoperative complications or recurrences during follow-up.

Conclusion: Repair of a tegmen bony defect with S53P4 bioactive glass granules seems to be safe and effective, limiting the use of the middle cranial fossa approach to cases with epitympanic defects and with an intact ossicular chain, and it could be used whatever the size of the defect and/or the presence of meningoencephalocele.

Level of evidence: 4.

KEYWORDS

bioactive glass, cholesteatoma, meningitis, meningoencephalocele, middle ear, tympanoplasty

This is an open access article under the terms of the Creative Commons Attribution-NonCommercial-NoDerivs License, which permits use and distribution in any medium, provided the original work is properly cited, the use is non-commercial and no modifications or adaptations are made.

© 2020 The Authors. *Laryngoscope Investigative Otolaryngology* published by Wiley Periodicals, Inc. on behalf of The Triological Society.

1 | INTRODUCTION

A defect at the tegmen of the temporal bone is a relatively frequent finding that the otologic surgeon has to repair. It can be associated with cerebrospinal fluid (CSF) leak or meningoencephalocele.¹ The most common cause is chronic otitis media (with or without cholesteatoma) and the bony defect may be due to previous surgical procedures and/or the pathology itself.² Less common causes are idiopathic, post-traumatic, postradiotherapy, or tumoral. Clinically, the tegmen bony defects can be asymptomatic or associated with non-specific otological symptoms: hearing loss, tinnitus, dizziness or instability, ear fullness, and chronic otorrhea. Sometimes, it can cause serious neurological complications such as meningitis, epidural abscess, or epilepsy.³

Because of the potential risk of serious complications, repair of the tegmen bony defect is advisable. Different surgical approaches have been described to repair this bony defect: the middle cranial fossa approach (MCFA) is generally considered the technique of choice in the case of a large bony defect; the transmastoid approach can be used in the case of a small defect.⁴

Mastoid obliteration is a well-known technique for rehabilitation of canal-wall-down mastoidectomies and for the surgical treatment of cholesteatoma either in canal-wall-up or canal-wall-down mastoidectomies.⁵ Although its safety and efficacy have largely been demonstrated in these clinical scenarios, the use of mastoid and epitympanic obliteration has not yet been studied for the repair of a tegmen bony defect, which is or is not associated with meningoencephalocele.

The aim of this study was to evaluate the surgical results and complications in a cohort of patients operated on to repair a tegmen bony defect using either a transmastoid approach with obliteration using S53P4 bioactive glass granules (TMA-O) or the classic middle cranial fossa approach (MCFA), and to try to define the optimal surgical strategy in different clinical situations.

2 | MATERIALS AND METHODS

This retrospective monocentric observational study was conducted in a tertiary otologic referral center. All patients gave the written informed consent for the use of their clinical data. Since it was a retrospective anonymous report of a standard technique, approval from the ethics committee was not necessary.

The inclusion criterion for this study was all patients operated on to repair a tegmen bony defect between December 2013 and July 2018.

2.1 | Preoperative assessment

All patients underwent:

- Otoscopy with microscope and endoscope: if otorrhea was present, a bacteriological test was performed using an ear swab.

- Audiometry for pure tones was performed in accordance with the ISO 8253-1 standards. The pure-tone average (PTA) was obtained from thresholds at frequencies of 500, 1000, 2000, and 4000 Hz in both air conduction (AC) and bone conduction (BC). The air-bone gap (ABG) was calculated. The ABG closure was defined as the difference between the preoperative and postoperative ABG.
- A high-resolution CT (HRCT) scan was performed in all patients and, in the case of suspected meningoencephalocele, MRI was also performed. The temporal bone CT acquisition was performed with secondary high-resolution reconstruction resulting in an in-plane resolution of 0.2 × 0.2 × 0.2 mm. The MRI studies were performed with a 3-T MR scanner and the acquisition, centered on the temporal bone, was composed of axial T1-weighted spin echo imaging, high-resolution 3D T2-weighted imaging, axial non-echo planar diffusion-weighted imaging (non-EP DWI) and diffusion-weighted sequences. Images were analyzed by the same neuroradiologist who was not aware of the surgical technique employed.^{6,7}

2.2 | Perioperative assessment

Data with regard to the presence or absence of cholesteatoma, the presence or absence of meningoencephalocele, a CSF leak, the status of the ossicular chain, and the location of the tegmen bony defect were collected from the surgical reports.

Following the technique used for the repair, the patients were divided into two groups: the TMA-O group and the MCFA group.

2.3 | Surgical techniques

All the procedures were performed under general anesthesia with a facial nerve monitor system (NIM, Medtronic, Minneapolis, Minnesota).

The TMA-O was performed via a retro-auricular skin incision. After the removal of the lesion, the tegmen bony defect was fully exposed, the status of the ossicular chain was checked and, in the case of a discontinuity in the ossicular chain, both malleus and incus were removed and an ossiculoplasty using a partial or total titanium prosthesis (Aerial Kurz, Tubingen, Germany) was performed regardless of whether the stapes arch was present or not. The removal of the two ossicles allowed the complete exposure of the edge of the bony defect in the case of a defect involving the attic. If a meningoencephalocele was present, it was coagulated with bipolar cautery: if this maneuver was sufficient to retract the herniated tissue intracranially, reconstruction was performed using a piece of cartilage over the defect and both mastoid and epitympanum were filled with bioactive glass granules (BonAlive, Turku, Finland) (Figure 1).

If there was a need for resection of the herniated tissue (with subsequent CSF leak), reconstruction of the dura was performed with a piece of temporalis fascia placed intracranially, and a piece of cartilage placed in the temporal bone defect and sealed with fibrin glue (Tisseel, Baxter International, Deerfield, Illinois). Obliteration with granules was performed as above.

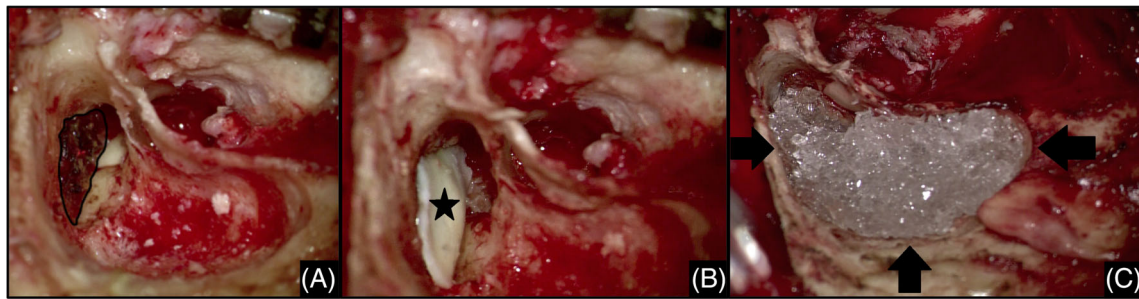
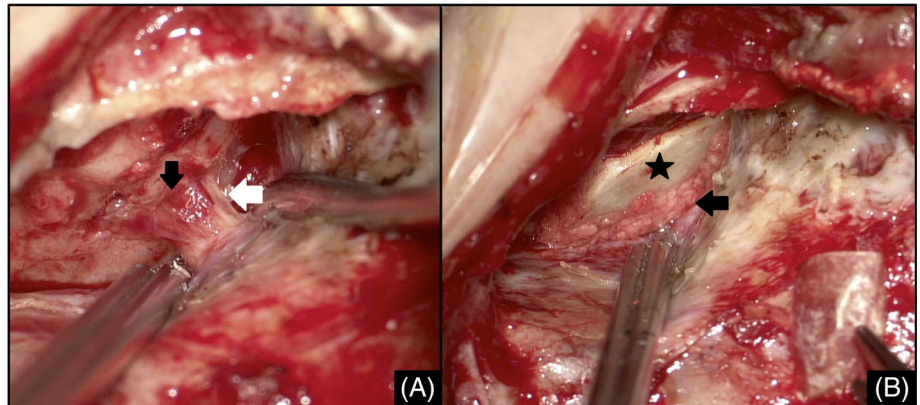


FIGURE 1 Intraoperative view of a right ear undergoing transmastoid obliteration repair of a large tegmen bony defect. A, Visualization of the edge of the bony defect (black line). B, A piece of cartilage (black star) is placed over the tegmen defect. C, Complete mastoid and epitympanic obliteration is then performed using S53P4 bioactive glass granules (black arrows)

FIGURE 2 Repair of a tegmen bony defect in a right ear through a middle cranial fossa approach. A, After visualizing the bony defect (black arrow) and the meningoencephalocele (white arrow), reconstruction is performed with a shell of bone (black star in B). B, The gap between the bony defect and the bone graft is sealed with bone dust (black arrow)



The technique used for the MCFA was as follows: craniotomy of dimensions 3 cm × 3 cm, elevation of the dura from the middle cranial fossa until all the edges of the bony defect were exposed. In the case of meningoencephalocele, the herniated tissue was cauterized and resected (Figure 2).

Closure of the defect was achieved by positioning several layers of material (fibrous tissue) over the dura, and a bony flap, larger than the bony defect, was placed intracranially: the gaps between the bony flap and the bony defect were sealed with bone dust and this reconstruction was covered with a second layer of fibrous tissue and fibrin glue.

2.4 | Postoperative assessment

Complications were noted in the early and late postoperative period. Patients undergoing MCFA had a postoperative HRCT scan during the period of hospitalization to detect intracranial postoperative complications.

All patients underwent postoperative otoscopy with audiometry during the follow-up 3-month period after surgery. All patients had a CT scan 1 year after surgery to detect any recurrence of the disease and osteointegration of the granules (Figure 3). If a cholesteatoma

was removed during the surgical procedure, an MRI was also performed using non-echo planar diffusion-weighted sequences.

2.5 | Statistical analysis

The statistical analysis was performed using XLSTAT 2016 (data analysis and statistical solution for Microsoft Excel; XLSTAT, Paris, France). Data are presented as mean ± SD. The differences in demographic data were calculated using the Student's *t* test or ANOVA for quantitative data and Fisher's exact test for qualitative data. Differences in ABG closure as well as differences in preoperative vs postoperative bone conduction thresholds and ABG were analyzed using a paired *t* test. For all comparisons, $P < .05$ was considered to indicate a statistically significant difference.

3 | RESULTS

3.1 | Population characteristics

In total, 24 patients were included in the study, undergoing surgery to repair a tegmen bony defect. Seventeen patients were operated on with TMA-O with obliteration using bioactive glass granules and six

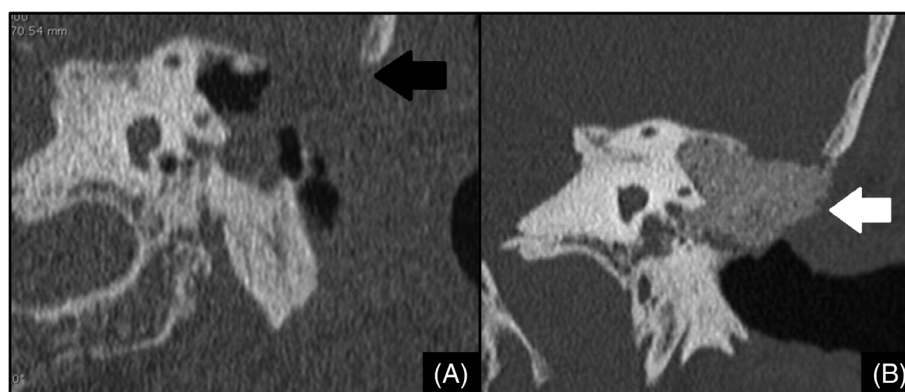


FIGURE 3 A, Preoperative coronal high-resolution CT (HRCT) image showing a large defect in the mastoid tegmen (black arrow) associated with a meningoencephalocele following multiple surgical procedures for cholesteatoma removal. This patient underwent surgery to repair a tegmen bony defect and rehabilitation of the canal-wall-down mastoidectomy using S53P4 bioactive glass granules. B, Postoperative HRCT image showed the stability of the reconstruction (white arrow) during the follow-up

TABLE 1 Patient demographics and characteristics

	TMA-O (n = 17)	MCFA (n = 7)	P value
Age (years)	49 ± 14	53 ± 17	.568 ^a
Sex (male)	12 (71%)	5 (71%)	.085 ^b
Previous otologic surgery			.021 ^b
0	3 (18%)	5 (71%)	
≥1	14 (82%)	2 (29%)	
Etiology			.259 ^c
COM	17 (100%)	4 (57%)	
Idiopathic	0	2 (29%)	
Post-traumatic	0	1 (14%)	
Preoperative PTA			
AC-PTA	51 ± 19.3	45 ± 18.3	.078 ^a
BC-PTA	21 ± 11.8	26 ± 12.3	.831 ^a
ABG	30 ± 12.8	19 ± 9.9	.012 ^a
Preoperative CT scan	17 (100%)	7 (100%)	
Size of the defect (mm)	6 ± 3.8	6 ± 3.5	.970 ^a
Discontinuity of the ossicular chain	15 (88%)	1 (14%)	.001 ^b
Preoperative MRI	8 (47%)	7 (100%)	
Cholesteatoma	5 (29%)	0	.272 ^b
Meningoencephalocele	4 (50%)	6 (86%)	.009 ^b

Abbreviations: ABG, air bone gap; AC-PTA, air conduction pure tone average; BC-PTA, bone conduction pure tone average; COM, chronic otitis media; MCFA, middle cranial fossa; PTA, pure tone average; TMA-O, transmastoid approach with obliteration.

^aStudent's t test.

^bFisher's exact test.

^cANOVA test.

patients (including one patient operated bilaterally) underwent surgery with MCFA. One patient underwent a combined approach (MCFA + TMA-O) to treat a 3-cm idiopathic defect present on all segments of

TABLE 2 Preoperative symptoms

	TMA-O (n = 17)	MCFA (n = 7)	P value (Fisher's exact test)
Vertigo	1 (6%)	0	1
Hearing loss	17	5 (71%)	.076
Otorrhea	13 (76%)	3 (43%)	.167
Otalgia	1 (6%)	1 (14%)	.507
Meningitis	1 (6%)	1 (14%)	.507

Abbreviations: MCFA, middle cranial fossa approach; TMA-O, transmastoid approach with obliteration.

the tegmen and with an intact ossicular chain. Obliteration using bioactive glass granules was also carried out in the mastoid to support the reconstruction of the bony defect in this region.

The characteristics of the patients operated on by TMA-O or MCFA and their symptomatology are presented in Tables 1 and 2. The mean age was 49 ± 14 years (range 28-77 years) in the TMA-O group and 53 ± 17 years (range 16-69 years) in the MCFA group. The main etiology of the tegmen bony defect was chronic otitis media in the TMA-O group (n = 17; 100%) and also in the MCFA group (n = 4; 57%). Fourteen patients (82%) in the TMA-O group had at least one previous otologic surgical procedure whereas only two patients (29%) in the MCFA group had undergone previous otologic surgery (tympanoplasty for cholesteatoma).

The main clinical symptom was hearing loss in both groups. Meningitis was a symptom revealing the presence of the tegmen bony defect in two cases, one in each group.

3.2 | Preoperative audiometry

The mean preoperative air and bone conduction thresholds were, respectively, 51 ± 19 dB and 21 ± 11 dB in the TMA-O group and

36 ± 12 dB and 20 ± 10 dB in the MCFA group. The average preoperative ABG was 30 ± 13 dB in the TMA-O group and 16 ± 4 dB in the MCFA group (P = .012).

3.3 | Preoperative imaging

In the preoperative HRCT scan, the mean size of the tegmen bony defect was estimated at 6 ± 3.8 mm in the TMA-O group (17 ears; 100%), and 6 ± 3.5 mm in the MCFA group (seven ears; 100%) (P = .969, Student's t test). There was a discontinuity in the ossicular chain in 15 ears (88%) in the TMA-O group and in one ear (14%) in the MCFA group (P = .001, Fisher's exact t test).

Preoperative MRI was performed in eight ears (47%) in the TMA-O group and in seven ears (100%) in the MCFA group. The studies revealed the presence of cholesteatoma in five ears (29%) in the TMA-O group and a meningoencephalocele in six ears (86%) in the MCFA group.

3.4 | Peri-operative findings

Results are summarized in Table 3. Cholesteatoma was present in 11 ears (65%) in the TMA-O group. As expected, in the MCFA group, the location of the defect was mostly anterior (tegmen tympani and/or tegmen antri in six of seven patients) compared to the TMA-O group; in the TMA-O group, there was a discontinuity in the ossicular chain in most of the cases (n = 15, 88%) compared to the MCFA group (n = 1, 14%) and the difference was statistically significant (P = .001, Fisher's exact test).

TABLE 3 Per-operative data

	TMA-O (n = 17)	MCFA (n = 7)	P value (Fisher)
Tegmen bony defect location			
Mastoid	6 (35%)	0	.130
Antri	4 (24%)	1 (14%)	1
Tympani	5 (29%)	0	.272
Tympani + antri	0	5 (71%)	<.001
Antri + mastoid	2 (12%)	1 (14%)	1
Size of the defect			.668
>5 mm	10 (59%)	5 (71%)	
<5 mm	7 (41%)	2 (29%)	
Discontinuity of the ossicular chain	15 (88%)	1 (14%)	.001
Cholesteatoma	11 (65%)	0	.006
Meningoencephalic herniation	7 (41%)	7	.018
CSF leak	2 (12%)	4 (57%)	.038

Abbreviations: CSF, cerebrospinal fluid; MCFA, middle cranial fossa approach; TMA-O, transmastoid approach with obliteration.

Seven cases (41%) in the TMA-O group had an associated meningoencephalocele compared to all patients (n = 7, 100%) in the MCFA group (P = .001, Fisher's exact test).

3.5 | Postoperative follow-up and complications

The mean follow-up was 22 ± 14 months (range 1-54 months) in the TMA-O group and 24 ± 15 months (range 3-58 months) in the MCFA group (NS).

In both groups, there were no early postoperative complications: patients were discharged at day 0 in the TMA-O group and at day 3 in the MCFA group. One patient in the TMA-O group experienced vertigo for 48 hours in the immediate postoperative period. This patient had a lateral semicircular canal fistula discovered intraoperatively.

Concerning the anatomical results, 3 months after surgery, all patients presented a well healed external auditory canal with an intact tympanic drum.

Regarding the audiological results, in the TMA-O group, the mean postoperative air and bone conduction thresholds were 38 ± 16 dB and 22 ± 11 dB, respectively, and the mean postoperative ABG was 16 ± 11.4 dB. In the MCFA group, the mean air and bone conduction thresholds were 45 ± 18 dB and 26 ± 12 dB, respectively, and the mean ABG was 19 ± 10 dB. The mean ABG closure was 14 ± 12 dB (P = .002, Student's paired t test) in the TMA-O group and -3 ± 7.3 dB in the MCFA group (P = .343, Student's paired t test). As expected, there was no statistically significant difference between pre- and postoperative mean air conduction thresholds in the MCFA group (P = .084) whereas in the TMA-O group the difference was statistically significant (P = .007, Student's paired t test) due to ossicular reconstruction and/or tympanic drum reconstruction. Likewise, there was no statistically significant difference between pre- and postoperative ABG in the MCFA group (P = .343, Student's paired t test) whereas in the TMA-O group, the difference was statistically significant (P = .002, Student's paired t test).

During the follow-up period, two patients in the TMA-O series underwent revision surgical procedures for reasons not related to repair of the tegmen bony defect: 1 recurrent cholesteatoma 12 months after the first surgery and 1 malposition of the ossicular chain replacement prosthesis treated with revision ossiculoplasty 18 months after the first surgery. Recurrent cholesteatoma occurred in the anterior epitympanum and was due to insufficient obliteration of this space. It was managed through a transcanal approach and a revision of the tegmen bony repair was not required since the defect was located in the mastoid.

3.6 | Postoperative imaging

Postoperative HRCT scan images were available for 16 patients in the TMA-O group (94%, one patient was lost at follow-up) and seven patients in the MCFA group (100%). In the first group, the HRCT images showed the persistence of the S53P4 bioactive glass granules sustaining the tegmen reconstruction in all patients without their resorption.

MRI studies (eight patients in the two groups combined) showed the presence of recurrent cholesteatoma in one patient in the TMA-O group 12 months after surgery; no other complications or recurrences were detected in the follow-up imaging studies.

4 | DISCUSSION

The objective of surgical treatment of a tegmen bony defect, which is or is not associated with meningoencephalocele is to restore osteo-dural integrity and remove the cholesteatoma and granulation tissue in the middle ear.⁸ Thus, a definitive separation between the cavities of the middle ear and the endocranial content provides protection against potential endocranial complications from the middle ear (meningitis, epidural abscess, brain abscess, and epilepsy).

Several surgical approaches have been advocated to repair tegmen defects. In the published literature, the choice of technique is governed by several parameters: the location and size of the bony defect, the existence of a meningoencephalocele, the preoperative hearing function, and the presence of chronic otitis media.⁹⁻¹³

The transmastoid approach is generally proposed only for small bony defects.^{9,14} In the literature, the MCFA is preferred when there is a large defect since, for large defects, the MCFA is supposed to provide better control of the edges of the defect and ensure a safer repair.^{3,10,15-17} An interesting technique was proposed by Marchioni

et al¹⁶ who combined the transmastoid approach with a minicraniotomy for the repair of the tegmen bony defect; this technique could be particularly interesting in the repair of a tegmen tympani bony defect with intact ossicular chain since it limits the extent of the craniotomy. A review of relevant articles is presented in Table 4.

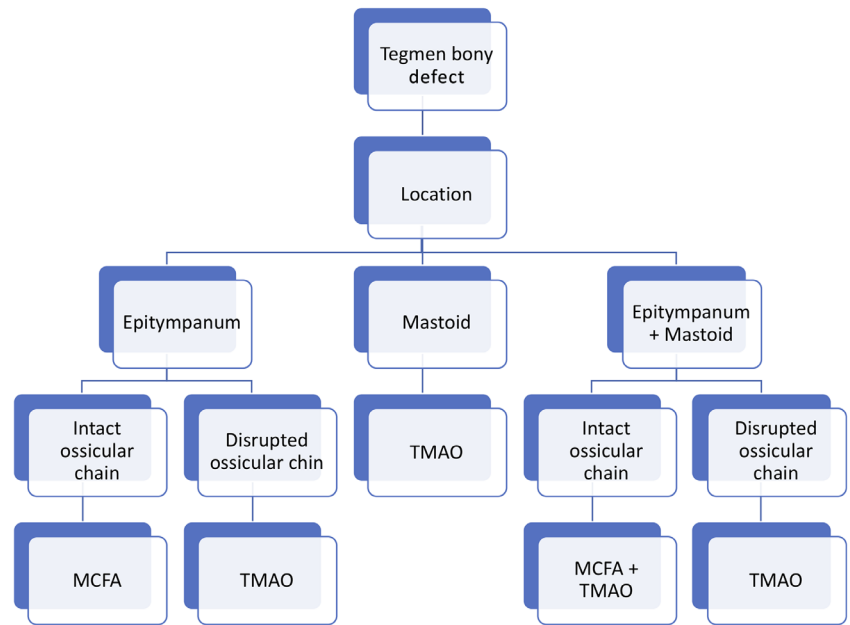
With this study, we aimed to evaluate the surgical results and complications associated with the two techniques used in our department to repair tegmen bony defects with or without encephalocele. Both are safe and effective, with the absence of major complications; the revision surgical procedures in the TMA-O group were not related to repair of the defect itself, but to the common complications of surgery for chronic otitis media (recurrent cholesteatoma and dislocation of ossicular prosthesis). We tried to demonstrate that the TMA-O could be used safely even in the case of a large bony defect. Another advantage of using this approach is that, even in the case of erosion of the external auditory canal, the obliteration prevents a canal-wall-down mastoidectomy from being performed since the defect in the external auditory canal could easily be repaired with obliteration. We started to use the obliteration technique in 2006 for chronic otitis media^{18,19} and progressively, we employed it to repair tegmen bony defects. The results of our study showed an evolution in the management of such conditions compared to what we published 20 years ago when obliteration was not employed in our department.³ Therefore, the choice between MCFA and the classic transmastoid approach without obliteration was only guided by the extent of the bony defect.

TABLE 4 The published articles most relevant to this study

Source (date)	Number of cases	Etiology	Surgical approach	Recurrence	Complications	Follow-up (months)
Mosnier et al. (2000)	15	COM 60% Cholesteatoma 33% Iatrogenic 7%	CA 73% MCFA 27%	0	0	24
Hoang et al. (2005)	30	Cholesteatoma 10% Traumatic 10% Spontaneous 80%	CA 17% MCFA 83%	1 CSF leak	3 facial paralysis 4 wound infections	8.5
Bodénez et al. (2008)	42	COM 24% Cholesteatoma 76%	CA 67% MCFA 19% TMA 14%	0	2 postoperative temporary CSF leaks	43
Sanna et al. (2009)	133	COM 21.8% Iatrogenic 45.9% Traumatic 7.5% Spontaneous 24.8%	CA 3% MCFA 27.8% MEO 41.4% TMA 27.8%	1 CSF leak 2 MEH	1 meningitis 1 extradural hematoma	38.4
Kari and Mattox et al. (2011)	56	Iatrogenic 29% Traumatic 12% Spontaneous 59%	CA 9% MCFA 7% MEO 9% TMA 75%	1 CSF leak	0	54
Grinblat et al. (2018)	262	COM + Cholesteatoma 47.7% Iatrogenic 20.9% Traumatic 8% Spontaneous 23.4%	CA 1.9% MCFA 19.1% MEO 46.2% TMA 32.8%	4 CSF leak 4 MEH	3 persistent CSF leak 1 extradural hematoma 1 meningitis 1 profound hearing loss	39.9

Note: None of published article described the obliteration technique in the management of a tegmen bony defect. Sanna et al⁴ and Grinblat et al¹² used the middle ear obliteration technique (subtotal petrosectomy with blind sac closure of the external auditory canal) in a significant percentage of patients. Abbreviations: CA, combined approach; COM, chronic otitis media; CSF, cerebrospinal fluid; MCFA, middle crania fossa; MEH, meningoencephalic herniation; MEO, middle ear obliteration; TMA, transmastoid approach.

FIGURE 4 Management of a bony defect at the tegmen of the temporal bone. Proposed flow chart to decide on a surgical approach. MCFA, middle cranial fossa approach; TMA-O, transmastoid approach with obliteration using S53P4 bioactive glass granules



The major point limiting the use of TMA-O is the presence of an epitympanic defect with an intact ossicular chain (Figure 4). Such a clinical condition is quite rare in chronic otitis media cases, since the ossicular chain is frequently interrupted, but could be seen with a spontaneous tegmen bony defect. Therefore, the MCFA should be limited to cases with an anterior defect and with an intact ossicular chain.

This observation has important clinical consequences. Despite the fact that the occurrence of serious intracranial complications is quite rare when performed by an experienced otologic team, the MCFA is still at risk of these, and should only be used when another less invasive technique is not feasible. Even with a very limited elevation of the dura from the tegmen, the MCFA remains an intracranial procedure and it cannot (at least in our country) be performed on a day-hospital basis.

In addition to being a less invasive procedure compared to the MCFA, the TMA-O is particularly cost-effective for a public health system. In this type of reconstruction, it is particularly advisable that the material used for the obliteration integrates some important characteristics since the TMA-O is mainly used in chronic otitis media cases. The material should be safe, even in the case of an infected ear. One could imagine that placing a biosynthetic material in an infected environment could facilitate the intracranial spreading of the infection through a tegmen bony defect. Moreover, the material should be stable over time without the risk of resorption. Indeed, the resorption could facilitate the recurrence of the pathology, especially in the case of meningoencephalocele.

The S53P4 bioactive glass granules possess both features; the antibacterial properties have been demonstrated both *in vitro*²⁰⁻²⁴ and by clinical studies *in vivo*^{18,25} and it could be used safely in the case of an active infection. The stability over time has recently been demonstrated by a radiological study on 70 cases.⁷ This bone

substitute was also used safely in several other clinical situations such as frontal sinus obliteration.²⁶

To our knowledge, this is the first report on the use of mastoid and epitympanic obliteration with S53P4 bioactive glass to repair a tegmen bony defect.

Grinblat et al recently published a large cohort of patients operated on with a MCFA and a TMA without obliteration.¹² They also employed a middle ear obliteration (with abdominal fat) with cul-de-sac closure of the external auditory canal in a significant percentage of patients (46.2%); the rationale of using this technique was the uncertain hearing results due to the previous surgical procedures, the presence of a chronically infected ear and large or multisite defects. We believe that the TMA-O technique with S53P4 could be safely used in such conditions and the middle ear obliteration with cul-de-sac closure of the external auditory should be reserved for the presence of a preoperative dead ear. As we demonstrated in this study, the ABG could improve after surgery and, in the case of absence of useful hearing improvement, the maintenance or restoration of an external auditory canal permits a rehabilitation with hearing aids.

There are several important limitations of this study that could affect the generalization of our results: being retrospective, it has intrinsic biases that are difficult to overcome. The choice of surgical technique was not randomized and there was no control group. In this clinical scenario, due also to the relative rarity of this situation, designing a prospective randomized clinical trial is not feasible or ethical, and all the published articles are based on retrospective analysis of a cohort of patients. Moreover, the follow-up period should be longer to confirm the validity of our results.

5 | CONCLUSION

The repair of a tegmen bony defect with S53P4 bioactive glass granules seems to be a safe and effective technique, limiting the use of

the middle cranial fossa approach to cases of epitympanic defects with an intact ossicular chain.

CONFLICT OF INTEREST

The authors have no funding, financial relationships, or conflicts of interest to disclose.

ORCID

Ghizlene Lahlou  <https://orcid.org/0000-0002-1067-045X>

Daniele Bernardeschi  <https://orcid.org/0000-0002-5937-8847>

REFERENCES

- Lundy LB, Graham MD, Kartush JM, LaRouere MJ. Temporal bone encephalocele and cerebrospinal fluid leaks. *Am J Otol.* 1996;17(3):461-469.
- Paparella MM, Meyerhoff WL, Oliviera CA. Mastoiditis and brain hernia (mastoiditis cerebri). *Laryngoscope.* 1978;88(7 Pt 1):1097-1106.
- Mosnier I, Fiky LE, Shahidi A, Sterkers O. Brain herniation and chronic otitis media: diagnosis and surgical management. *Clin Otolaryngol Allied Sci.* 2000;25(5):385-391.
- Sanna M, Fois P, Paolo F, Russo A, Falcioni M. Management of meningoencephalic herniation of the temporal bone: personal experience and literature review. *Laryngoscope.* 2009;119(8):1579-1585.
- Schimanski G, Schimanski E. Obliteration of mastoid cavities: 30 years of experience with recommendations for surgical strategy. *HNO.* 2015;63(8):538-545.
- De Foer B, Vercruyse J-P, Bernaerts A, et al. Middle ear cholesteatoma: non-echo-planar diffusion-weighted MR imaging versus delayed gadolinium-enhanced T1-weighted MR imaging - value in detection. *Radiology.* 2010;255(3):866-872.
- Bernardeschi D, Law-Ye B, Bielle F, et al. Bioactive glass granules for mastoid and epitympanic surgical obliteration: CT and MRI appearance. *Eur Radiol.* 2019;29(10):5617-5626.
- Jackson R, Addison AB, Prinsley PR. Cholesteatoma in children and adults: are there really any differences? *J Laryngol Otol.* 2018;132(7):575-578.
- Sergi B, Passali GC, Picciotti PM, De Corso E, Paludetti G. Transmastoid approach to repair meningoencephalic herniation in the middle ear. *Acta Otorhinolaryngol Ital.* 2013;33(2):97-101.
- Semaan MT, Gilpin DA, Hsu DP, Wasman JK, Megerian CA. Transmastoid extradural-intracranial approach for repair of transtemporal meningoencephalocele: a review of 31 consecutive cases. *Laryngoscope.* 2011;121(8):1765-1772.
- Kari E, Mattox DE. Transtemporal management of temporal bone encephaloceles and CSF leaks: review of 56 consecutive patients. *Acta Otolaryngol (Stockh).* 2011;131(4):391-394.
- Grinblat G, Dandinaraiah M, Prasad SC, et al. Temporal bone meningo-encephalic-herniation: etiological categorization and surgical strategy. *Otol Neurotol.* 2018;39(3):320-332.
- Bodénez C, Bernat I, Vitte E, Lamas G, Tankéré F. Temporal breach management in chronic otitis media. *Eur Arch Otorhinolaryngol.* 2008;265(11):1301-1308.
- Wootten CT, Kaylie DM, Warren FM, Jackson CG. Management of brain herniation and cerebrospinal fluid leak in revision chronic ear surgery. *Laryngoscope.* 2005;115(7):1256-1261.
- Hoang S, Ortiz Torres MJ, Rivera AL, Litofsky NS. Middle cranial fossa approach to repair tegmen defects with autologous or alloplastic graft. *World Neurosurg.* 2018;118:e10-e17.
- Marchioni D, Bonali M, Alicandri-Ciuffelli M, Rubini A, Pavesi G, Presutti L. Combined approach for tegmen defects repair in patients with cerebrospinal fluid otorrhea or herniations: our experience. *J Neurol Surg Part B Skull Base.* 2014;75(4):279-287.
- Carlson ML, Copeland WR, Driscoll CL, et al. Temporal bone encephalocele and cerebrospinal fluid fistula repair utilizing the middle cranial fossa or combined mastoid-middle cranial fossa approach. *J Neurosurg.* 2013;119(5):1314-1322.
- Bernardeschi D, Nguyen Y, Russo FY, Mosnier I, Ferrary E, Sterkers O. Cutaneous and labyrinthine tolerance of bioactive glass S53P4 in mastoid and epitympanic obliteration surgery: prospective clinical study. *Biomed Res Int.* 2015;2015:242319.
- Bernardeschi D, Nguyen Y, Mosnier I, Smail M, Ferrary E, Sterkers O. Use of granules of biphasic ceramic in rehabilitation of canal wall down mastoidectomy. *Eur Arch Otorhinolaryngol.* 2014;271(1):59-64.
- Munukka E, Leppäranta O, Korkeamäki M, et al. Bactericidal effects of bioactive glasses on clinically important aerobic bacteria. *J Mater Sci Mater Med.* 2008;19(1):27-32.
- Drago L, Vassena C, Fenu S, et al. In vitro antibiofilm activity of bioactive glass S53P4. *Future Microbiol.* 2014;9(5):593-601.
- Drago L, Toscano M, Bottagisio M. Recent evidence on bioactive glass antimicrobial and antibiofilm activity: a mini-review. *Materials (Basel).* 2018;11(2):326.
- Drago L, De Vecchi E, Bortolin M, Toscano M, Mattina R, Romanò CL. Antimicrobial activity and resistance selection of different bioglass S53P4 formulations against multidrug resistant strains. *Future Microbiol.* 2015;10(8):1293-1299.
- Zhang D, Leppäranta O, Munukka E, et al. Antibacterial effects and dissolution behavior of six bioactive glasses. *J Biomed Mater Res A.* 2010;93(2):475-483.
- Vos J, de Vey MP, Colnot D, Borggrevén P, Orelío C, Quak J. Bioactive glass obliteration of the mastoid significantly improves surgical outcome in non-cholesteatomatous chronic otitis media patients. *Eur Arch Otorhinolaryngol.* 2017;274(12):4121-4126.
- Stoor P, Grénman R. Bioactive glass and turbinate flaps in the repair of nasal septal perforations. *Ann Otol Rhinol Laryngol.* 2004;113(8):655-661.

How to cite this article: Remangeon F, Lahlou G, Alciato L, et al. Management of tegmen defects with mastoid and epitympanic obliteration using S53P4 bioactive glass. *Laryngoscope Investigative Otolaryngology.* 2020;5:297-304. <https://doi.org/10.1002/lio2.374>