



HAL
open science

The clinical, genetic, and immune landscape of meningioma in patients with NF2-schwannomatosis

Grace E Gregory, Abdurrahman I Islim, Cathal John Hannan, Adam P Jones, Charlotte Hammerbeck-Ward, Scott A Rutherford, Simon R Freeman, Simon Lloyd, Michel Kalamarides, Miriam J Smith, et al.

► To cite this version:

Grace E Gregory, Abdurrahman I Islim, Cathal John Hannan, Adam P Jones, Charlotte Hammerbeck-Ward, et al.. The clinical, genetic, and immune landscape of meningioma in patients with NF2-schwannomatosis. *Neuro-Oncology Advances*, 2023, 5 (Supplement_1), pp.i94-i104. 10.1093/noajnl/vdac127. hal-04509159

HAL Id: hal-04509159

<https://hal.sorbonne-universite.fr/hal-04509159v1>

Submitted on 18 Mar 2024

HAL is a multi-disciplinary open access archive for the deposit and dissemination of scientific research documents, whether they are published or not. The documents may come from teaching and research institutions in France or abroad, or from public or private research centers.

L'archive ouverte pluridisciplinaire **HAL**, est destinée au dépôt et à la diffusion de documents scientifiques de niveau recherche, publiés ou non, émanant des établissements d'enseignement et de recherche français ou étrangers, des laboratoires publics ou privés.



Distributed under a Creative Commons Attribution - NonCommercial 4.0 International License

The clinical, genetic, and immune landscape of meningioma in patients with NF2-schwannomatosis

Grace E. Gregory[†], Abdurrahman I. Islim[†], Cathal John Hannan, Adam P. Jones, Charlotte Hammerbeck-Ward, Scott A. Rutherford, Simon R. Freeman, Simon Lloyd, Michel Kalamarides, Miriam J. Smith, Kevin Couper, Catherine A. McBain, Michael D. Jenkinson, David Brough, Andrew T. King, D. Gareth Evans, and Omar N. Pathmanaban

Geoffrey Jefferson Brain Research Centre, Manchester Academic Health Science Centre, Northern Care Alliance NHS Group, University of Manchester, Manchester, UK (G.E.G., A.I.I., C.J.H., A.P.J., K.C., D.B., A.T.K., O.N.P.); Division of Neuroscience and Experimental Psychology, School of Biological Sciences, Faculty of Biology, Medicine and Health, University of Manchester, Manchester, UK (G.E.G., A.I.I., D.B., O.N.P.); The Lydia Becker Institute of Immunology and Inflammation, University of Manchester, Manchester, UK (G.E.G., A.D.P., K.C., D.B.); Department of Neurosurgery, Manchester Centre for Clinical Neurosciences, Salford Royal Hospital NHS Foundation Trust, Salford, UK (A.I.I., C.J.H., C.H.-W., S.A.R., A.T.K., O.N.P.); Division of Immunology, Immunity to Infection and Respiratory Medicine, School of Biological Sciences, Faculty of Biology, Medicine and Health, University of Manchester, Manchester, UK (A.P.J., K.C.); Department of Ears, Nose and Throat, Manchester Centre for Clinical Neurosciences, Salford Royal Hospital NHS Foundation Trust, Salford, UK (S.R.F., S.L.); Department of Neurosurgery, Sorbonne Université Pitié-Salpêtrière, Paris, France (M.K.); Division of Evolution, Infection and Genomics, School of Biological Sciences, Faculty of Biology, Medicine and Health, University of Manchester, Manchester, UK (M.J.S., D.G.E.); Manchester Centre for Genomic Medicine, Manchester Academic Health Science Centre, St Mary's Hospital, Manchester University NHS Foundation Trust, Manchester, UK (M.J.S., D.G.E.); Department of Clinical Oncology, The Christie NHS Foundation Trust, Manchester, UK (C.A.M.); Institute of Systems, Molecular and Integrative Biology, University of Liverpool, Liverpool, UK (M.D.J.); Department of Neurosurgery, The Walton Centre NHS Foundation Trust, Liverpool, UK (M.D.J.); Division of Cardiovascular Sciences, School of Medical Sciences, Faculty of Biology, Medicine and Health, University of Manchester, Manchester, UK (C.J.H., A.T.K.)

Corresponding Authors: Abdurrahman I. Islim, MPhil (Abdurrahman.Islim@manchester.ac.uk); Omar N. Pathmanaban, PhD, FRCS (SN) (Omar.Pathmanaban@manchester.ac.uk), Manchester Centre for Clinical Neurosciences, Salford Royal Hospital, Manchester, M6 8FT, UK; Geoffrey Jefferson Brain Research Centre, Manchester Academic Health Science Centre, University of Manchester, Manchester, M13 9NQ, UK.

[†]*These authors are co-first authors*

Abstract

NF2-schwannomatosis is the most common genetic predisposition syndrome associated with meningioma. Meningioma in NF2-schwannomatosis is a major source of morbidity and mortality. This is due to accumulative tumor burden in patients with synchronous schwannomas and ependymomas, sometimes including complex collision tumors. Balancing the impact of multiple interventions against the natural history of various index tumors, and the ongoing risk of de novo tumors over an individual's lifetime makes decision-making complex. The management of any given individual meningioma is often different from a comparable sporadic tumor. There is typically a greater emphasis on conservative management and tolerating growth until a risk boundary is reached, whereby symptomatic deterioration or higher risk from anticipated future treatment is threatened. Management by high-volume multidisciplinary teams improves quality of life and life expectancy. Surgery remains the mainstay treatment for symptomatic and rapidly enlarging meningioma. Radiotherapy has an important role but carries a higher risk compared to its use in sporadic disease. Whilst bevacizumab is effective in NF2-associated schwannoma and cystic ependymoma, it has no value in the management of meningioma. In this review, we describe the natural history of the disease, underlying genetic, molecular, and immune microenvironment changes, current management paradigms, and potential therapeutic targets.

Keywords

clinical management | meningioma | *NF2* | NF2-schwannomatosis | tumor microenvironment.

Meningioma and NF2-Schwannomatosis

Epidemiology

Inherited and acquired pathogenic variants in the *NF2* gene lead to the tumor predisposition syndrome, neurofibromatosis type 2, which is now called NF2-schwannomatosis.¹ This highly penetrant autosomal dominant condition has an incidence of 1/25 000 to 1/33 000 and is classically characterized by the development of bilateral vestibular schwannomas (VS).^{2,3} Additionally, patients with NF2-schwannomatosis often experience the growth of other nonmalignant tumors in the central nervous system (CNS), such as meningioma and ependymomas found in 48%–75% and up to 65% of patients respectively.⁴ Accounting for 38% of all CNS tumors, most meningioma occurs sporadically in patients without NF2-schwannomatosis and are categorized into World Health Organization (WHO) grades 1–3 for nonmalignant, atypical, and anaplastic neoplasms respectively.⁵ However, 60% of sporadic meningioma have somatic mutations in the *NF2* gene, suggestive of potential commonalities in the pathophysiology of sporadic and NF2-associated meningioma.⁶ Sporadic meningioma occurs more frequently in adult women than adult men overall, a pattern which is replicated in NF2-associated meningioma.^{4,6} Female patients with NF2-schwannomatosis display twice as many intracranial neoplasms when compared to males and also have a higher risk of developing multiple meningioma.^{7,8} However, meningioma tends to arise in males with NF2-schwannomatosis at a younger age.⁹

Diagnostic Criteria of NF2-Schwannomatosis

While the presence of bilateral VS is pathognomonic of NF2-schwannomatosis, other additional criteria have been recently recognized as part of the revised Manchester criteria (Table 1).^{10,11} A diagnosis of NF2-schwannomatosis is also possible in the absence of these criteria in patients with

multiple meningioma or in young patients (age <25 years) with a solitary meningioma, albeit at a lower likelihood (5% and 40%, respectively).^{12,13} Like *NF2* pathogenic variants, *SMARCE1* pathogenic variants may predispose multiple meningioma (7%), and pediatric meningioma (14%).^{12–14} Given the implications of this diagnosis for patients and their offspring, screening patients with multiple meningioma and young patients with a solitary meningioma for NF2-schwannomatosis and *SMARCE1* variants may be of value, as well as genetic counseling. A previous link between pediatric meningioma and Neurofibromatosis Type 1 (NF1) was shown but limited by the inclusion of patients diagnosed prior to the wide acceptance of NF2-schwannomatosis as being a distinct tumor predisposition syndrome.^{15,16} The case descriptions provided by the authors were more in keeping with NF2-schwannomatosis, and population-based studies of patients with NF1 have revealed no increased risk of meningioma formation.¹⁷

Clinical Presentation of Meningioma in NF2-Schwannomatosis

Comprehensive data on the mode of presentation for meningioma in NF2-schwannomatosis are lacking. A longitudinal study of 358 meningioma in 92 patients demonstrated that around 80% were asymptomatic, discovered through cranial and spinal magnetic resonance imaging (MRI) as part of the diagnostic work-up or during interval monitoring. The remainder, like their sporadic counterparts, gave rise to general symptoms, including headaches (13%) and seizures (13%), as well as focal symptoms such as a motor deficit (11%) and cranial nerve palsy (10%).¹⁸ Approximately 10% of asymptomatic NF2-associated meningioma demonstrate rapid growth during follow-up (with a growth rate of ≥ 2 cm³/year) and de novo meningioma arise in a fifth of patients.^{18,19} Given this, any new symptoms or changes to the patient's neurological examination should prompt imaging assessment for the burden of meningioma disease or any other NF2-associated tumors.

Table 1. Revised Manchester Criteria for Diagnosis of NF2-Schwannomatosis

1	Bilateral VS in <70 years of age
2	Unilateral VS in <70 years and an FDR with NF2-schwannomatosis
3	FDR with NF2-schwannomatosis or unilateral VS and 1 of the following: glioma, neurofibroma, non-vestibular schwannoma, cataracts, or cerebral calcification. In patients with a unilateral VS and ≥ 2 non-intradermal schwannomas, a negative LZTR1 test is required
4	≥ 2 meningioma and 2 of the following: VS, glioma, neurofibroma, non-vestibular schwannoma, cataracts, or cerebral calcification
5	Constitutional or mosaic pathogenic <i>NF2</i> gene variant in blood or 2 identical variants in 2 distinct tumors

Abbreviations: NF2, neurofibromatosis type 2; VS, vestibular schwannoma; FDR, first-degree relative.

Pathogenic Variants Associated With NF2-Schwannomatosis

The NF2 Gene and Mutational Variance

In 1993, the gene on Chromosome 22q12.2 encoding a previously unknown moesin-, ezrin-, and radixin-like protein, henceforth called merlin, was determined to be the mutated tumor suppressor in NF2-schwannomatosis.²⁰ The *NF2* gene encodes 17 exons which, through alternative splicing, form the 10 known isoforms of merlin. The most common forms are isoforms I and II which are differentially encoded by exons 1–15 and 17, or 1–16, respectively.²¹

Approximately 50% of NF2-schwannomatosis cases arise through inherited pathogenic variants in the *NF2* gene, although pathogenic variants in exons 16 and 17 have not been described.² The NF2-schwannomatosis condition serves as a canonical example of Knudson's two-hit hypothesis: afflicted patients have a germline inactivating variant in one *NF2* allele, with an acquired somatic mutation of the second allele acting as the initiating event for tumor formation.^{22,23} Mild to moderate NF2-schwannomatosis (previously referred to as "Gardner-type NF2") is genetically characterized by missense variants, large single or multi-exon deletion, duplication or truncation variants in exon 1, or splice site variants affecting exons 8-15 of the *NF2* gene.^{2,24,25} The severe, early onset "Wishart-type" form of NF2-schwannomatosis has fully truncating variants in exons 2–13 of the *NF2* gene which renders the protein inactive or may cause a dominant negative protein that escapes nonsense-mediated decay.^{24,26}

Alternatively to familial inheritance, the 22q12.2 *NF2* gene location is an area of increased genetic instability and has been found to harbor a high de novo variant incidence of 50%–60% in NF2-schwannomatosis cases.^{2,27} Up to 60% of patients have de novo *NF2* mutations that were acquired somatically, post-fertilization.^{28,29} Therefore, only a proportion of cells are affected resulting in a mosaic phenotype, which is typically the mildest form of NF2-schwannomatosis and can include anatomically segmental disease.²⁴

NF2 Pathogenic Variants in Meningioma Can Lead to Dysfunctional Merlin

Whether somatic or constitutional, different *NF2* variants confer a variation in meningioma development risk. In a study of 411 patients with NF2-schwannomatosis, it was demonstrated that variants nearer the 5' end of the *NF2* gene in exons 4–6 or 1–3 have the highest likelihood of developing cranial meningioma (in 81% and 70% of patients, respectively), compared to variants occurring closer to the 3' end in exons 14-15 that confer a diminished risk (28%).⁹ Mechanistically, the less severe disease observed in patients with variants at the 3' end of *NF2* may be due variants at these loci that lead to the development of a partially functioning merlin protein, as these variants map to the actin-binding C-terminus.^{21,30} Whereas, high-risk variants at the 5' end of the gene lead to a loss of tumor suppressor functionality within the abnormal protein, mapping

instead to merlin's domain linkers and sub-domains A and B of the FERM (4.1, ezrin, radixin, and moesin) region.^{21,30} Functional merlin acts as a scaffolding protein involved in linking the actin cytoskeleton and transmembrane proteins at cell-cell junctions and in cell-matrix interactions.^{31,32} This pertains to its key function as a tumor suppressor protein that maintains contact inhibition and regulates oncogenic signaling pathways in healthy tissues as shown in [Figure 1](#).³¹⁻³⁷

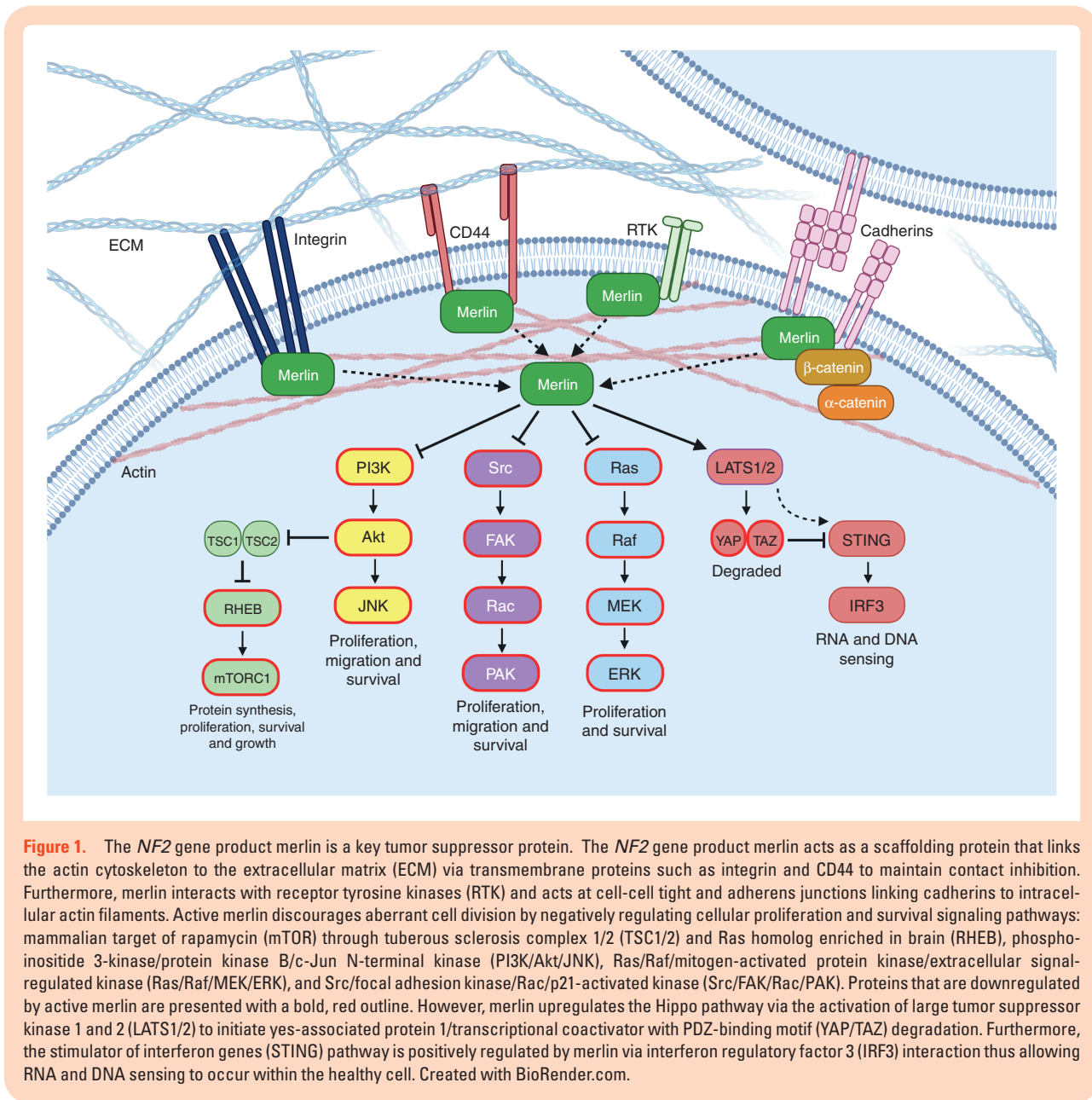
Natural History of NF2-Associated Meningioma

Cellular and Developmental Origin

Although there is a relative paucity of studies examining the developmental origin of the human meninges, a landmark study in this area utilized sections of the meninges of human embryos from developmental stages 8–23 (equating to 3 to 8 postovulatory weeks) to demonstrate distinct embryological origins of anatomically discrete areas of the meninges.³⁸ The authors determined that cells of both neural crest and mesodermal origin contributed to the formation of the meninges, and later work expanded on this finding to establish that the meninges of the anterior skull base, cerebral convexity, tentorium, and falx cerebri were predominantly of neural crest origin, and that of the posterior fossa was derived from the mesoderm.³⁹⁻⁴¹ The individual embryological origin of anatomically distinct areas of the meninges is likely to be of relevance to meningioma development. A striking co-localization between meninges of neural crest origin and the site of *NF2* mutated meningioma has been observed, where 77% of meningioma arising from neural crest-derived meninges were found to have single nucleotide pathogenic variants or large deletions of *NF2* in a genetic analysis of over 350 meningioma.⁴² Although a causal mechanism accounting for the predilection of *NF2* mutated meningioma to emerge from meninges of neural crest origin has yet to be definitively established, the merlin-regulated Hippo pathway has been implicated in the development and migration of neural crest-derived tissues.⁴³

Tumor Growth Patterns and Multiplicity

More than half of NF2-schwannomatosis patients present with meningioma with a cumulative incidence of up to 75% of patients by the age of 70.^{9,19,44} Multiplicity is common and the mean number of meningioma per patient in a study of 119 patients was 5.¹⁹ Their location varies but they are commonly found along the skull base in pediatric patients presenting early with meningioma.⁴⁵ On the other hand, tumors in adults commonly develop in convexity, parasagittal, and parasagittal locations.⁴⁵ The growth patterns of these tumors vary considerably within individual patients.^{9,46} The first study of the natural history of untreated NF2-associated meningioma followed 17 patients harboring 135 meningioma and reported four distinct growth patterns: quiescent tumors demonstrating <0.03 cm³ of growth over 6 months;



tumors demonstrating linear growth of $>0.03 \text{ cm}^3$ between two-time points; tumors with a saltatory growth pattern, characterized by alternating periods of quiescence and linear growth, and finally tumors demonstrating an exponential growth pattern.⁸ Examples of each of these growth patterns in NF2-associated meningioma are provided in [Figure 2](#). Subsequent large-scale natural history studies of NF2-associated meningioma have found that the majority (60%–83%) display either no growth, or very slow growth (defined as $<1 \text{ mm}$ increase in maximal diameter or $<2 \text{ cm}^3$ in volume/year) over a prolonged period of observation.^{18,19,46}

Clinical and Radiological Predictors of Growth

The first study of the long-term natural history of NF2-associated meningioma identified younger age at onset

and female gender as factors increasing the risk of meningioma progression following diagnosis.⁸ A radiological scoring system, initially developed for use in incidental sporadic meningioma, has recently been validated for use in NF2-associated meningioma.¹⁸ The Asan Intracranial Meningioma Scoring System ascribes higher scores to meningioma of larger volume, demonstrating T2 hyperintensity on MRI, associated with peri-tumoral edema and absence of intralesional calcification on imaging, and has been demonstrated to provide a good estimate of the risk of rapid growth of sporadic and NF2-associated meningioma.^{18,47} However, no individual factor or scoring system is completely predictive of the future behavior of NF2-associated meningioma, highlighting the requirement for lifelong radiological follow-up of patients diagnosed with NF2-schwannomatosis.⁴⁸

The Tumor Microenvironment of NF2-Associated Meningioma

The Extracellular Matrix

The tumor microenvironment (TME) of NF2-associated meningioma also comprises infiltrating immune cells, secreted extracellular matrix (ECM) proteins, ECM proteases, cytokines, and growth factors, as illustrated in [Figure 3](#).⁴⁹⁻⁵¹ Differential expression and secretion of ECM components have been used to differentiate between WHO grade 1 and 2 meningioma and their individual subtypes, but not between sporadic and NF2-associated meningioma.⁵¹⁻⁵³ Laminin, fibronectin, collagen IV, and proteoglycans are high molecular weight proteins ubiquitously expressed across human tissues and are essential structural components in the ECM.^{53,54} Matrix remodeling in tumors is associated with extensive fibrosis, blood vessel collapse, and exacerbated TME hypoxia^{55,56}; fibrosis is common in meningioma and is associated with tumor recurrence.⁵⁷ Matrix metalloproteinases (MMPs) can degrade larger components of the ECM, such as collagen IV, and are key proteins involved in brain and bone-invasive meningioma.⁵¹ More specifically, high expression of MMP2 or MMP9 correlates with increased recurrence rates and brain invasion in aggressive subtypes of meningioma.^{51,58,59} When combined with low expression of TIMP metalloproteinase inhibitor 1 (TIMP1), an inhibitor of MMPs, there is an increased risk of microcyst formation and edema occurring in the adjacent brain parenchyma.⁶⁰

The Immune Microenvironment

In addition to the mechanical protection of the CNS, the meninges are now known to act as an immunologically active barrier that samples and responds to inflammatory signals.^{61,62} For example, cytokines and molecules in the cerebrospinal fluid and brain parenchyma interstitial fluid, contribute to immune cell activation in the meningeal lymphatic vasculature.⁶³ The majority of the meningeal immune cell compartment is composed of myeloid cells, such as monocytes and their macrophage derivatives which is reflected in the high proportion of tumor-associated macrophages (TAM) within meningioma tissue that dominate over other infiltrating immune cell types.^{50,64,65} As of yet, no studies have determined if meningioma significantly modulate the surrounding meningeal immune landscape, or whether the meningeal lymphatic system influences immune cell recruitment to the TME of meningioma to affect tumor growth or symptom severity. However, vascular endothelial growth factor secreted by arachnoid and dural border cells is known to promote angiogenesis and increase vascular permeability for further immune cell infiltration into meningioma.^{66,67}

Classically activated macrophages, known as M1 macrophages, polarize upon stimulation by lipopolysaccharides and secrete pro-inflammatory cytokines such as interleukins IL-1 β and IL-18. This promotes a pro-inflammatory, anti-tumorigenic effect in the tumor tissue and is thought to be the dominant macrophage subtype in specific meningioma with a 22q deletion or monosomy 22.⁶⁸ However, in the majority of meningioma, up to 18% of the tumor is composed of alternatively-activated M2 macrophages

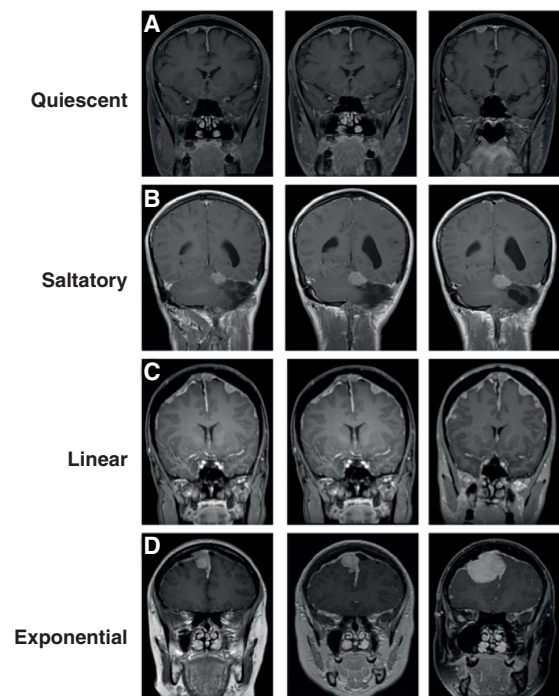


Figure 2. Natural history of NF2-associated meningioma. Each row depicts T1 weighted, contrast-enhanced coronal MRI scans of the brain from patients with NF2-schwannomatosis. Each scan undertaken one year apart, with the most recent scan on the right. (A) Quiescent: Right convexity meningioma demonstrating no significant change in volume during follow-up. (B) Saltatory: Left tentorial meningioma demonstrating an initial volume increase between the first and second scans, with subsequent stabilization. (C) Linear: Slowly progressive increase in volume of multiple convexity and parasagittal meningioma during follow-up. (D) Exponential: A right parasagittal meningioma demonstrating a small increase in tumor volume between the first and second scans, with a subsequent dramatic increase in volume one year later, leading to the development of neurological deficits and necessitating surgical resection.

that display anti-inflammatory, pro-tumorigenic qualities.⁵⁰ Stimulation by IL-4, IL-13, and colony-stimulating factor 1 (CSF1) induces M2 macrophages to secrete anti-inflammatory cytokines such as IL-10 and transforming growth factor. A study of 30 patients confirmed a correlation between M2 macrophage infiltration and an increase in meningioma growth and recurrence that evidences the pro-tumorigenic activity of M2 TAMs.⁵⁰ Interestingly, the elevated expression of the CSF1 receptor (CSF1R) on M2 TAMs has been observed in 29 patients with malignant meningioma who also presented with increased levels of CSF1 in the blood which has the potential to be used as a biomarker for tumor burden.⁶⁹ Additionally, the ratio of M2:M1 macrophages present in meningioma correlates with increased meningioma recurrence and therefore may act as a prognostic marker for patients with meningioma.⁵⁰

As well as myeloid cells, lymphoid cells such as T cells, natural killer cells and, to a lesser extent, B cells have been found to cluster in the meninges, as well as the perivascular spaces of meningioma.^{49,61} T cells express programmed cell

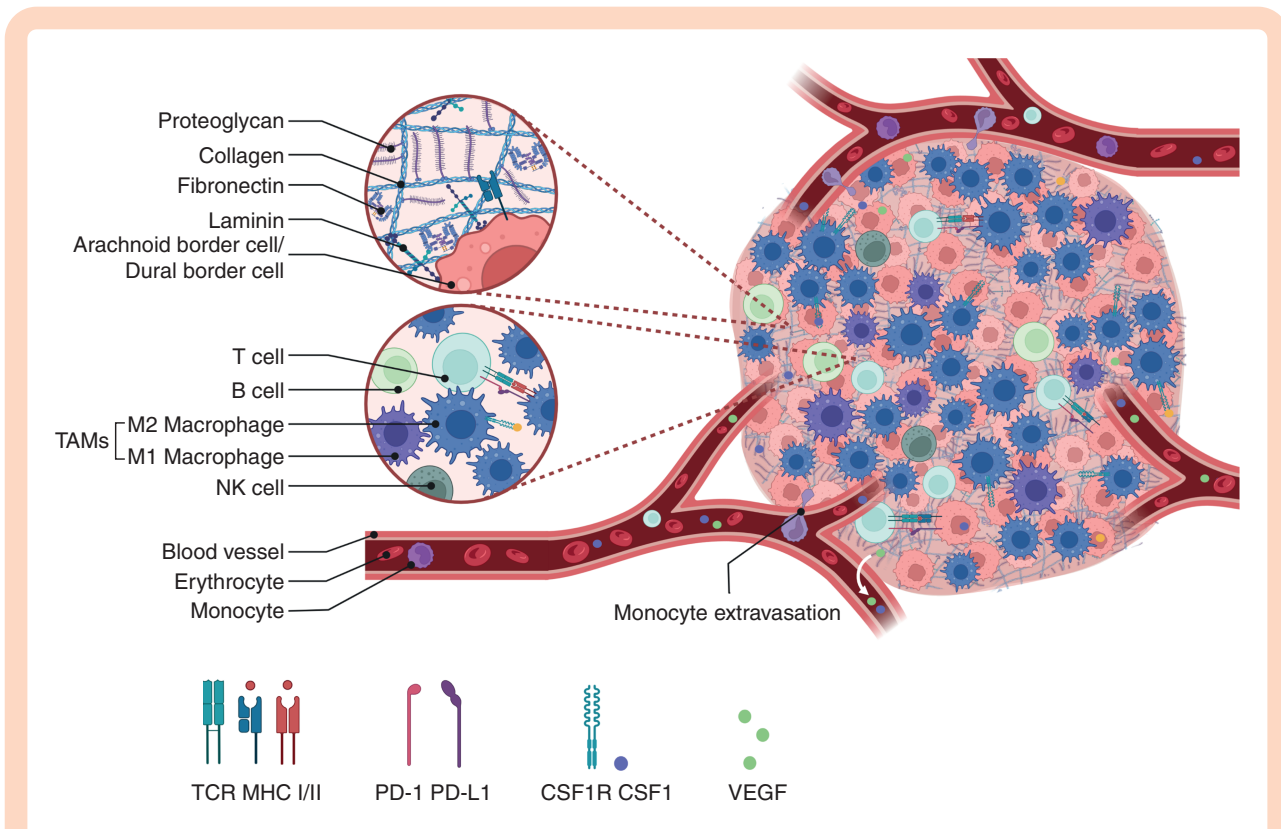


Figure 3. The tumor microenvironment of NF2-associated meningioma. TME of NF2-associated meningioma, the extracellular matrix (ECM) of secreted proteins, proteoglycans and enzymes is interspersed with meningioma tumor cells derived from arachnoid and dural border cells expressing major histocompatibility complex I (MHC I). Vascularization occurs upon vascular endothelial growth factor (VEGF) secretion from arachnoid and dural border cells, as well as macrophages which stimulate increased angiogenesis and vascular permeabilization. Meningioma reside outside the blood brain barrier which permits the extravasation of peripheral myeloid-derived immune cells into the tumor tissue, such as monocytes that polarize into either M1/M2 TAM. M2 TAMs overexpress CSF1R to bind growth factor CSF1, and express PD-L1 and MHC II. Lymphoid immune cells such as T cells that display T cell receptors (TCR) and PD-1, as well as B cells and natural killer (NK) cells become suppressed in the tumor microenvironment (TME), therefore, reducing antitumor immunity. Created with BioRender.com.

death protein 1 (PD-1) receptors important for restraining potent pro-inflammatory responses, at the cost of impairing the anti-tumor T cell response. However, some meningioma exhibit overexpression of PD-L1, the ligand of PD-1 on cytotoxic T cells, and therefore mediates suppression of downstream anti-tumor immunity.^{70,71} As such, T cells display antigen-experience and exhaustion within meningioma tumors.⁴⁹

Clinical Management and Quality of Life Outcomes

Factors Underpinning Decision Making

Management of NF2-associated meningioma should be undertaken in high-volume centers with multidisciplinary teams, which improves quality of life (QoL) and life expectancy.⁴⁴ Owing to the asymptomatic nature of most meningioma, and their slow growth, active monitoring is the most widely adopted initial strategy for meningioma management.¹⁸ However, as discussed earlier, the growth characteristics of meningioma vary across and within patients and therefore the intervals for monitoring remain

undefined, albeit lifelong. Surgery is the first-line treatment for symptomatic and/or rapidly growing tumors. Principles of meningioma surgery with regards to maximizing the extent of resection whilst preserving neurological integrity apply. These principles are often conflicting, never more so than in NF2-schwannomatosis where surgery is the mainstay of tumor control yet should not add to the morbidity of the condition. Radiotherapy and radiosurgery are reserved for recurrent tumors and growing tumors in surgically challenging locations. Radiation should be used with caution due to the risk of malignant transformation, the formation of radiation-induced tumors,⁷² and the risk of cognitive deficits.⁷³ Some NF2-schwannomatosis patients exhibit progressive raised intracranial pressure related to superior sagittal sinus or other venous sinus tumor burden; ophthalmological monitoring is important in these cases.⁷⁴ Cerebrospinal fluid diversion is sometimes needed to protect against visual loss. Overall, management approaches are highly individualized and consider the patient's age, functional status, the tumors present, and their likely natural history, priorities of different synchronous tumors and involve shared decision-making around the aim of treatment, durability of disease control, adverse effects, and possible health-related QoL outcomes.

Surgery

Surgery remains the first-line treatment for symptomatic and rapidly enlarging meningioma with the aim being to relieve or prevent neurological deterioration, maintain QoL, and obtain tissue for diagnosis.⁷⁵ Surgical approaches should consider the presence of any nearby meningioma which may be accessible without increasing the risk of surgical morbidity and mortality, and which may require intervention in the near future due to high-risk features such as hyperintensity on T2 weighted MRI and the presence of peri-tumoral edema.^{18,19} When planning the surgical resection of an NF2-associated meningioma, consideration must be given to the site of previous incisions and craniotomies, given the high number of surgical procedures that NF2-schwannomatosis patients are likely to undergo in their lifetimes.⁴⁴ The majority of NF2-associated meningioma arise at the cerebral convexity or along the falx cerebri, and are therefore distant from the eloquent neurovascular structures found at the skull base,¹⁸ but complex tumors affecting the optic apparatus and skull base do occur and require management with the full range of microscopic and endoscopic techniques. At the convexities, particular attention should be paid to the surgical approach for meningioma encroaching or encasing the superior sagittal sinus. In sporadic tumors, some neurosurgeons advocated for complete resection including tumors within the sinus^{76,77} followed by sinus reconstruction, but this is associated with a higher rate of morbidity and mortality.⁷⁸ To circumvent the increased risk of venous infarcts and potential neurological deficits,⁷⁹ a hybrid approach combining subtotal resection followed by active monitoring or adjuvant radiation is currently in favor, depending on the volume of residual meningioma and tumor grade.⁷⁵ Surgical approaches may also consider the presence of other symptomatic tumors such as those in the context of collision schwannoma-meningioma tumors, which due to their erratic growth behavior, can compromise hearing and brain stem function rapidly.⁸⁰ Surgical resection should be delayed in patients with a recent history of bevacizumab administration if possible, due to the known association between the use of this drug and wound breakdown.⁸¹

Operated symptomatic and growing NF2-associated meningioma appear to be histologically more aggressive than sporadic meningioma (52% WHO grades 2 and 3).¹⁸ Moreover, the rates of subsequent recurrence and the requirement for future re-intervention are higher in tumors undergoing subtotal resection.¹⁹ No studies have assessed the perioperative morbidity associated with NF2-associated meningioma, however, a population-based study of 184 patients showed no cases of mortality within 30 days, a similar rate to patients with sporadic tumors.⁸² The presence of meningioma in patients with NF2-schwannomatosis impairs QoL.⁸³ However it is unknown what effect meningioma surgery has on QoL in these patients. In sporadic tumors, surgery relieves neurological deficits and improves short-term QoL.⁸⁴ In the long term, a significant decrease in QoL is observed, notably with cognitive difficulties, emotional and social dysfunction, as well as sleep disorders and fatigue.⁸⁵ Risk factors for worsened QoL include increased tumor burden and number

of operations and it is, therefore, likely that such deficits are present long-term in NF2-schwannomatosis patients, partly due to meningioma and ensuing treatment.⁸⁶

Radiosurgery and Radiotherapy

Several case series have advocated stereotactic radiosurgery (SRS) to growing or symptomatic NF2-associated meningioma. These have included 12 to 39 patients (number of meningioma 99–204) with median follow-up periods ranging between 4 and 9 years.^{87–90} The 5-year local control rates were >90%. No cases of malignant transformation were reported. The overall meningioma burden or distant failure rate was reported in some studies ranging between 27% and 51%.^{87,89,90} Additionally, the risk of distant failure in one study was related to the number of SRS treatments.⁹⁰ Overall mortality ranged from 17 to 33%. Data on fractionated radiotherapy use is limited but demonstrates similar local control rates.⁹¹

Radiation seems to improve local control however concerns regarding malignant transformation and radiation induced tumors persist. In patients who died within these series, data on causes of death or autopsy reports were not always available. Yet despite some cases (3%–33% of overall study populations) describing the cause of death as “multiple de novo” and “progressive” meningioma,^{87,90} the risk of transformation into a higher-grade meningioma with aggressive behavior is not acknowledged. Moreover, in a large natural history study of 74 patients followed-up for a mean of 9 years, the risk of de novo meningioma formation was 16%,¹⁹ lower than the reported local failure rates in these reports. Importantly, a clear link between radiation treatment and subsequent malignancy/malignant progression in NF2-schwannomatosis has been shown more recently in a larger well ascertained cohort of irradiated NF2-schwannomatosis patients, including malignant progression to grade 3 meningioma.⁹²

Overall QoL in meningioma patients treated with radiotherapy may be lower than in those treated with surgery.⁹³ Specifically, in a study of 118 patients with NF2, patients whose treatment included any form of radiotherapy had a worse QoL than patients who did not,⁹⁴ although it is worth considering that the need for radiotherapy may have been due to a more aggressive disease course, also predictive of a worse QoL.⁹⁵

Therefore, caution is advised with the use of radiotherapy for meningioma in NF2. Longer-term studies are necessary to adequately assess the risks of malignant transformation and radiation-induced tumors by evaluating incidences of new tumors within and outside the radiation field, and long-term health-related QoL.

Novel Treatments and Clinical Trials

Targeting Aberrant Molecular Pathways

Drugs to combat several aberrant molecular pathways have been or are currently being investigated (Table 2). Two phase II trials investigating mammalian target of

Table 2. Completed or Ongoing Clinical Trials Investigating Drug Therapy for Meningioma in NF2-Schwannomatosis

Registration Number	Drug	Phase	Tumor Target	Molecular Target	Status
NCT02831257	AZD2014	II	Meningioma	mTOR	Completed; results available
NCT01419639	RAD001	II	NF2-associated tumours	mTOR	Completed; results available
NCT02333565	RAD001 and octreotide	II	Meningioma	mTOR	Completed; results available
NCT00973739	Lapatinib	II	NF2-associated tumors	RTK	Completed; results available
NCT02934256	Icotinib	II	NF2-associated tumors	RTK	Completed; awaiting results
NCT03095248	Selumetinib	II	NF2-associated tumors	MEK	Active; recruiting
NCT04374305	Brigatinib	II	NF2-associated tumors	FAK	Active; recruiting
NCT02523014	GSK2256098	II	Meningioma	FAK	Active; recruiting
NCT05130866	REC-2282	II/III	Meningioma	PI3K/Akt	Active; not yet recruiting

Abbreviations: NF2, neurofibromatosis type 2; mTOR, mammalian target of rapamycin; RTK, receptor tyrosine kinase; MEK, mitogen-activated protein kinase; FAK, focal adhesion kinase; PI3K/Akt, phosphoinositide 3-kinase/protein kinase B.

rapamycin (mTOR) inhibitors, AZD2014 and RAD001, have been completed. The recent trial utilizing the dual mTORC1/mTORC2 inhibitor AZD2014 for patients with NF2-schwannomatosis and progressive or symptomatic meningioma had 12/18 patients withdraw from the study due to side effects (NCT02831257). The RAD001 trial conversely had a 90% completion rate and demonstrated slowing of meningioma growth, although none of the tumors reduced in size in comparison to baseline (NCT01419639). A combinatory phase II study assessing RAD001, in addition to octreotide, which had an additive antiproliferative effect on meningioma in vitro, demonstrated a slowing in median growth rates from 16.6% during the three months leading up to participation compared to 0.02% in the first three months of the study and 0.48%, after three to six months on treatment. Four out of 20 patients had NF2-schwannomatosis.⁹⁶ Analysis of eight patients treated with lapatinib, an inhibitor of the receptor tyrosine kinase activity of epidermal growth factor receptor, demonstrated slower volumetric growth rates of meningioma whilst on treatment compared to off therapy.⁹⁷ Clearly more work is required and other trials are currently underway (Table 2).

Targeting the Immune Microenvironment

Given the dominant immunological footprint present within meningioma, employment of immune-based drugs and therapies have great potential to enhance anti-tumoral immunity. Whilst traditional routes like checkpoint inhibition of the PD-1/PD-L1 axis may not be as effective in meningioma, due to poor expression of PD-L1 within the TME⁹⁸ and phase II trials using anti-PD-1 drug nivolumab showing no benefit in cases of sporadic meningioma,⁹⁹ targeting TAM polarization through CSF1R inhibition may be a superior alternative. Preclinical murine models of human malignant meningioma illustrated CSF1R blockade using monoclonal antibodies significantly reduced tumor growth and induced transcriptional reprogramming in TAMs.⁶⁹ Beyond the use of drugs, adoptive cell therapies utilize the patient's own tumor-specific immune cells to expand *ex vivo* and reintroduce to generate a robust antitumoral response. Chimeric antigen receptor T-cells against the immune checkpoint B7-H3 were deployed in a patient with anaplastic meningioma, and whilst an effective response was generated, recurrent tumor tissue was found to downregulate B7-H3.¹⁰⁰ Thus, immunotherapy for NF2-schwannomatosis patients with meningioma is a promising treatment, but immunoediting and antigen loss are major hurdles to overcome for these treatments to be successful.

Recommendations and Areas for Future Research

The management of meningioma in patients with NF2-schwannomatosis presents a substantial challenge. Practice points largely arise from single-center retrospective and prospective studies and would benefit from larger multi-center studies of the natural history of meningioma and comparative intervention studies. The following practice points are recommended:

1. NF2-schwannomatosis patients should be managed through high-volume multidisciplinary centers.
2. The first-line management strategy for asymptomatic meningioma should be active imaging surveillance. This should be lifelong. No studies are available currently to advise on the intervals for monitoring, although local policies exist and advise annual MRI once meningioma are identified until individual growth rates are established.⁴⁴
3. Surgery should be reserved for symptomatic, rapidly enlarging tumors or tumors growing to risk boundaries where further growth would risk neurological deficits, increase morbidity, or reduce efficacy of anticipated future treatments. Radiotherapy can achieve adequate local tumor control in the short-medium term in selected patients where surgical options are higher risk, however, its use should be with caution due to the risk of malignant transformation. Ophthalmological follow-up is recommended.
4. The option of a clinical trials should be explored with patients.

Future research may focus on factors predictive of meningioma growth and post-operative outcomes using a “meningiomics” approach incorporating patient, imaging, tumor, and blood characteristics to stratify treatment and optimize follow-up.¹⁰¹ This would also allow the development of non-invasive biomarkers to monitor disease status and assess treatment targets. Studies of QoL are also important to assess for the impact of surgery, radiation, and other treatment options to aid decision-making. The interrogation of aberrant molecular pathways and the immune system in NF2-associated meningioma is ongoing and have the potential to identify novel treatments for people with NF2-schwannomatosis.

Funding

The authors did not receive any funding for completion of this work.

Conflict of interest statement. G.E.G., A.P.J., K.C., D.B., and O.N.P. have received funding from NF2 BioSolutions UK. A.I.I. is supported by the NIHR Academic Clinical Fellowship Scheme. C.J.H., A.T.K., and O.N.P. are funded by Eleanor Peel Trust, the Royal College of Surgeons of Edinburgh, and the BMA Foundation. S. L. and D.G.E. are supported by the Manchester NIHR Biomedical Research Centre (IS-BRC-1215-20007). O.N.P. is UK Chief Investigator for Recursion Pharma Rec 2282 phase II/III RCT in NF2 mutated meningioma; A.I.I. is sub principal investigator.

Supplement sponsorship. This supplement was sponsored by a generous donation from Mr. Paul Mielnik and his family to help raise awareness and advance the care of patients with meningiomas worldwide.

References

1. Plotkin SR, Messiaen L, Legius E, et al. Updated diagnostic criteria and nomenclature for neurofibromatosis type 2 and schwannomatosis: an international consensus recommendation [published online ahead of print June 8, 2022]. *Genet Med*. doi:10.1016/j.gim.2022.05.007.
2. Evans DG, Huson SM, Donnai D, et al. A genetic study of type 2 neurofibromatosis in the United Kingdom. I. Prevalence, mutation rate, fitness, and confirmation of maternal transmission effect on severity. *J Med Genet*. 1992;29(12):841–846.
3. Evans DGR, Moran A, King A, et al. Incidence of vestibular schwannoma and neurofibromatosis 2 in the North West of England over a 10-year period: higher incidence than previously thought. *Otol Neurotol*. 2005;26(1):93–97.
4. Mautner VF, Lindenau M, Baser ME, et al. The neuroimaging and clinical spectrum of neurofibromatosis 2. *Neurosurgery*. 1996;38(5):880–885.
5. Ostrom QT, Cioffi G, Gittleman H, et al. CBRUS statistical report: primary brain and other central nervous system tumors diagnosed in the United States in 2012–2016. *Neuro Oncol*. 2019;21(suppl 5):v1–v100.
6. Papi L, De Vitis LR, Vitelli F, et al. Somatic mutations in the neurofibromatosis type 2 gene in sporadic meningiomas. *Hum Genet*. 1995;95(3):347–351.
7. Lawson McLean A, Rosahl S. Gender-specific growth dynamics of neurofibromatosis type-2-related tumors of the central nervous system. *Acta Neurochir*. 2016;158(11):2127–2134.
8. Dirks MS, Butman JA, Kim HJ, et al. Long-term natural history of neurofibromatosis type 2-associated intracranial tumors: Clinical article. *J Neurosurg*. 2012;117(1):109–117.
9. Smith MJ, Higgs JE, Bowers NL, et al. Cranial meningiomas in 411 neurofibromatosis type 2 (NF2) patients with proven gene mutations: clear positional effect of mutations, but absence of female severity effect on age at onset. *J Med Genet*. 2011;48(4):261–265.
10. Smith MJ, Bowers NL, Bulman M, et al. Revisiting neurofibromatosis type 2 diagnostic criteria to exclude LZTR1-related schwannomatosis. *Neurology*. 2017;88(1):87–92.
11. Evans DG, King AT, Bowers NL, et al. Identifying the deficiencies of current diagnostic criteria for neurofibromatosis 2 using databases of 2777 individuals with molecular testing. *Genet Med*. 2019;21(7):1525–1533.
12. Pathmanaban ON, Sadler KV, Kamaly-Asl ID, et al. Association of genetic predisposition with solitary schwannoma or meningioma in children and young adults. *JAMA Neurol*. 2017;74(9):1123–1129.
13. Hannan CJ, Hammerbeck-Ward C, Pathmanaban ON, et al. Multiple meningiomas as a criterion for the diagnosis of neurofibromatosis type 2 and other tumor predisposition syndromes. *Neurosurgery* 2022;90(6):793–799.
14. Smith MJ, Wallace AJ, Bennett C, et al. Germline SMARCE1 mutations predispose to both spinal and cranial clear cell meningiomas. *J Pathol*. 2014;234(4):436–440.
15. Kanter WR, Eldridge R, Fabricant R, Allen JC, Koerber T. Central neurofibromatosis with bilateral acoustic neuroma: genetic, clinical and biochemical distinctions from peripheral neurofibromatosis. *Neurology*. 1980;30(8):851–859.
16. Grossbach AJ, Mahaney KB, Menezes AH. Pediatric meningiomas: 65-year experience at a single institution. *J Neurosurg Pediatr*. 2017;20(1):42–50.

17. McLaughran JM, Harris DI, Donnai D, et al. A clinical study of type 1 neurofibromatosis in north west England. *J Med Genet.* 1999;36(3):197–203.
18. Abi Jaoude S, Peyre M, Degos V, et al. Validation of a scoring system to evaluate the risk of rapid growth of intracranial meningiomas in neurofibromatosis type 2 patients. *J Neurosurg.* 2020;134(5):1377–1385.
19. Goutagny S, Bah AB, Henin D, et al. Long-term follow-up of 287 meningiomas in neurofibromatosis type 2 patients: clinical, radiological, and molecular features. *Neuro Oncol.* 2012;14(8):1090–1096.
20. Rouleau GA, Merel P, Lutchman M, et al. Alteration in a new gene encoding a putative membrane-organizing protein causes neuro-fibromatosis type 2. *Nature.* 1993;363(6429):515–521.
21. Cooper J, Giancotti FG. Molecular insights into NF2/Merlin tumor suppressor function. *FEBS Lett.* 2014;588(16):2743–2752.
22. Knudson AG. Hereditary cancer: two hits revisited. *J Cancer Res Clin Oncol.* 1996;122(3):135–140.
23. Evans DG, Sainio M, Baser ME. Neurofibromatosis type 2. *J Med Genet.* 2000;37(12):897–904.
24. Halliday D, Emmanouil B, Pretorius P, et al. Genetic Severity Score predicts clinical phenotype in NF2. *J Med Genet.* 2017;54(10):657–664.
25. Gardner WJ, Frazier CH. Bilateral acoustic neurofibromas: a clinical study and field survey of a family of five generations with bilateral deafness in thirty-eight members. *Arch Neurol Psychiatr.* 1930;23(2):266–302.
26. Wishart JH. Case of tumours in the skull, dura mater, and brain. *Edinb Med Surg J.* 1822;18(72):393–397.
27. Evans D, Howard E, Giblin C, et al. Birth incidence and prevalence of tumor-prone syndromes: estimates from a UK family genetic register service. *Am J Med Genet A.* 2010;152A(2):327–332.
28. Evans DG, Hartley CL, Smith PT, et al. Incidence of mosaicism in 1055 de novo NF2 cases: much higher than previous estimates with high utility of next-generation sequencing. *Genet Med.* 2020;22(1):53–59.
29. Louvrier C, Pasmant E, Briand-Suleau A, et al. Targeted next-generation sequencing for differential diagnosis of neurofibromatosis type 2, schwannomatosis, and meningiomatosis. *Neuro Oncol.* 2018;20(7):917–929.
30. Gutmann DH, Geist RT, Xu H, Kim JS, Saporito-Irwin S. Defects in neurofibromatosis 2 protein function can arise at multiple levels. *Hum Mol Genet.* 1998;7(3):335–345.
31. Stamenkovic I, Yu Q. Merlin, a “magic” linker between extracellular cues and intracellular signaling pathways that regulate cell motility, proliferation, and survival. *Curr Protein Pept Sci.* 2010;11(6):471–484.
32. Lallemand D, Curto M, Saotome I, Giovannini M, McClatchey AI. NF2 deficiency promotes tumorigenesis and metastasis by destabilizing adherens junctions. *Genes Dev.* 2003;17(9):1090–1100.
33. Morrison H, Sherman LS, Legg J, et al. The NF2 tumor suppressor gene product, merlin, mediates contact inhibition of growth through interactions with CD44. *Genes Dev.* 2001;15(8):968–980.
34. Okada T, Lopez-Lago M, Giancotti FG. Merlin/NF-2 mediates contact inhibition of growth by suppressing recruitment of Rac to the plasma membrane. *J Cell Biol.* 2005;171(2):361–371.
35. Morrison H, Sperka T, Manent J, et al. Merlin/neurofibromatosis type 2 suppresses growth by inhibiting the activation of Ras and Rac. *Cancer Res.* 2007;67(2):520–527.
36. Petrilli AM, Fernández-Valle C. Role of Merlin/NF2 inactivation in tumor biology. *Oncogene.* 2016;35(5):537–548.
37. Meng F, Yu Z, Zhang D, et al. Induced phase separation of mutant NF2 imprisons the cGAS-STING machinery to abrogate antitumor immunity. *Mol Cell.* 2021;81(20):4147–4164.e7.
38. O’Rahilly R, Müller F. The meninges in human development. *J Neuropathol Exp Neurol.* 1986;45(5):588–608.
39. Couly GF, Le Douarin NM. Mapping of the early neural primordium in quail-chick chimeras. II. The prosencephalic neural plate and neural folds: implications for the genesis of cephalic human congenital abnormalities. *Dev Biol.* 1987;120(1):198–214.
40. Jiang X, Iseki S, Maxson RE, Sucov HM, Morriss-Kay GM. Tissue origins and interactions in the mammalian skull vault. *Dev Biol.* 2002;241(1):106–116.
41. Yoshida T, Vivatbutsi P, Morriss-Kay G, Saga Y, Iseki S. Cell lineage in mammalian craniofacial mesenchyme. *Mech Dev.* 2008;125(9-10):797–808.
42. Okano A, Miyawaki S, Hongo H, et al. Associations of pathological diagnosis and genetic abnormalities in meningiomas with the embryological origins of the meninges. *Sci Rep.* 2021;11(1):6987.
43. Hindley CJ, Condurat AL, Menon V, et al. The Hippo pathway member YAP enhances human neural crest cell fate and migration. *Sci Rep.* 2016;6:23208.
44. Forde C, King AT, Rutherford SA, et al. Disease course of neurofibromatosis type 2: a 30-year follow-up study of 353 patients seen at a single institution. *Neuro Oncol.* 2021;23(7):1113–1124.
45. Li P, Wu T, Wang Y, et al. Clinical features of newly developed NF2 intracranial meningiomas through comparative analysis of pediatric and adult patients. *Clin Neurol Neurosurg.* 2020;194:105799.
46. Evers S, Verbaan D, Sanchez E, Peerdeman S. 3D Volumetric measurement of neurofibromatosis type 2-Associated meningiomas: association between tumor location and growth rate. *World Neurosurg.* 2015;84(4):1062–1069.
47. Lee EJ, Kim JH, Park ES, et al. A novel weighted scoring system for estimating the risk of rapid growth in untreated intracranial meningiomas. *J Neurosurg.* 2017;127(5):971–980.
48. Evans DGR, Baser ME, O’Reilly B, et al. Management of the patient and family with neurofibromatosis 2: a consensus conference statement. *Br J Neurosurg.* 2005;19(1):5–12.
49. Fang L, Lowther DE, Meizlish ML, et al. The immune cell infiltrate populating meningiomas is composed of mature, antigen-experienced T and B cells. *Neuro Oncol.* 2013;15(11):1479–1490.
50. Proctor DT, Huang J, Lama S, et al. Tumor-associated macrophage infiltration in meningioma. *Neurooncol Adv.* 2019;1(1):vdz018.
51. Kwon MJ, Sung CO, Kang SY, Do IG, Suh YL. Differential expression of extracellular matrix-related genes in rare variants of meningioma. *Hum Pathol.* 2013;44(2):260–268.
52. Sofela AA, Hilton DA, Ammoun S, et al. Fibulin-2: a novel biomarker for differentiating grade II from grade I meningiomas. *Int J Mol Sci.* 2021;22(2):E560.
53. Caffo M, Caruso G, Galatioto S, et al. Immunohistochemical study of the extracellular matrix proteins laminin, fibronectin and type IV collagen in secretory meningiomas. *J Clin Neurosci.* 2008;15(7):806–811.
54. Engel J, Furthmayr H. Electron microscopy and other physical methods for the characterization of extracellular matrix components: laminin, fibronectin, collagen IV, collagen VI, and proteoglycans. *Methods Enzymol.* 1987;145:3–78.
55. Jain RK, Martin JD, Stylianopoulos T. The role of mechanical forces in tumor growth and therapy. *Annu Rev Biomed Eng.* 2014;16:321–346.
56. Chauhan VP, Martin JD, Liu H, et al. Angiotensin inhibition enhances drug delivery and potentiates chemotherapy by decompressing tumour blood vessels. *Nat Commun.* 2013;4:2516.
57. Hess K, Spille DC, Adeli A, et al. Occurrence of fibrotic tumor vessels in grade I meningiomas is strongly associated with vessel density, expression of VEGF, PIGF, IGFBP-3 and tumor recurrence. *Cancers (Basel).* 2020;12(10):E3075.
58. Das A, Tan VL, Smith DR. Expression of extracellular matrix markers in benign meningiomas. *Neuropathology.* 2003;23(4):275–281.
59. Okada M, Miyake K, Matsumoto Y, et al. Matrix metalloproteinase-2 and matrix metalloproteinase-9 expressions correlate with the recurrence of intracranial meningiomas. *J Neurooncol.* 2004;66(1-2):29–37.
60. Paek SH, Kim DG, Park CK, et al. The role of matrix metalloproteinases and tissue inhibitors of matrix metalloproteinase in microcystic meningiomas. *Oncol Rep.* 2006;16(1):49–56.

61. Alves de Lima K, Rustenhoven J, Kipnis J. Meningeal immunity and its function in maintenance of the central nervous system in health and disease. *Annu Rev Immunol*. 2020;38:597–620.
62. Song E, Mao T, Dong H, et al. VEGF-C-driven lymphatic drainage enables immunosurveillance of brain tumours. *Nature* 2020;577(7792):689–694.
63. Louveau A, Plog BA, Antila S, et al. Understanding the functions and relationships of the glymphatic system and meningeal lymphatics. *J Clin Invest*. 2017;127(9):3210–3219.
64. Van Hove H, Martens L, Scheyltjens I, et al. A single-cell atlas of mouse brain macrophages reveals unique transcriptional identities shaped by ontogeny and tissue environment. *Nat Neurosci*. 2019;22(6):1021–1035.
65. Garzon-Muvdi T, Bailey DD, Pernik MN, Pan E. Basis for immunotherapy for treatment of meningiomas. *Front Neurol*. 2020;11:945.
66. Goel HL, Mercurio AM. VEGF targets the tumour cell. *Nat Rev Cancer*. 2013;13(12):871–882.
67. Reszec J, Hermanowicz A, Rutkowski R, et al. Expression of MMP-9 and VEGF in meningiomas and their correlation with peritumoral brain edema. *Biomed Res Int*. 2015;2015:646853.
68. Domingues PH, Teodósio C, Otero A, et al. Association between inflammatory infiltrates and isolated monosomy 22/del(22q) in meningiomas. *PLoS One*. 2013;8(10):e74798.
69. Yeung J, Yaghoobi V, Miyagishima D, et al. Targeting the CSF1/CSF1R axis is a potential treatment strategy for malignant meningiomas. *Neuro Oncol*. 2021;23(11):1922–1935.
70. Karimi S, Mansouri S, Mamatjan Y, et al. Programmed death ligand-1 (PD-L1) expression in meningioma; prognostic significance and its association with hypoxia and NFkB2 expression. *Sci Rep*. 2020;10(1):14115.
71. Du Z, Abedalthagafi M, Aizer AA, et al. Increased expression of the immune modulatory molecule PD-L1 (CD274) in anaplastic meningioma. *Oncotarget*. 2015;6(7):4704–4716.
72. Evans DGR, Birch JM, Ramsden RT, Sharif S, Baser ME. Malignant transformation and new primary tumours after therapeutic radiation for benign disease: substantial risks in certain tumour prone syndromes. *J Med Genet*. 2006;43(4):289–294.
73. Krull KR, Hardy KK, Kahalley LS, Schuitema I, Kesler SR. Neurocognitive outcomes and interventions in long-term survivors of childhood cancer. *J Clin Oncol*. 2018;36(21):2181–2189.
74. Maria Bacci G, Giordano F, Sardi I, et al. Optical coherence tomography significance in managing complex neurofibromatosis 2-related papilledema: Report of a case. *JRSM Open*. 2021;12(1):2054270420981454.
75. Goldbrunner R, Stavrinou P, Jenkinson MD, et al. EANO guideline on the diagnosis and management of meningiomas. *Neuro Oncol*. 2021;23(11):1821–1834.
76. Chernov M. Meningiomas of the superior sagittal sinus. *J Neurosurg*. 2007;106(4):736–737; author reply 737.
77. DiMeco F, Li KW, Casali C, et al. Meningiomas invading the superior sagittal sinus: surgical experience in 108 cases. *Neurosurgery*. 2004;55(6):1263–1272; discussion 1272–1274.
78. Sindou M, Hallacq P. Venous reconstruction in surgery of meningiomas invading the sagittal and transverse sinuses. *Skull Base Surg*. 1998;8(2):57–64.
79. Giordan E, Sorenson TJ, Lanzino G. Optimal surgical strategy for meningiomas involving the superior sagittal sinus: a systematic review. *Neurosurg Rev*. 2020;43(2):525–535.
80. Adib SD, Tatagiba M. Surgical management of collision-tumors between vestibular schwannoma and meningioma in the cerebellopontine angle in patients with neurofibromatosis type 2. *Acta Neurochir (Wien)*. 2019;161(6):1157–1163.
81. Morris KA, Golding JF, Axon PR, et al. Bevacizumab in neurofibromatosis type 2 (NF2) related vestibular schwannomas: a nationally coordinated approach to delivery and prospective evaluation. *Neurooncol Pract*. 2016;3(4):281–289.
82. Champeaux-Depond C, Weller J, Resche-Rigon M. Neurofibromatosis type 2: A nationwide population-based study focused on survival after meningioma surgery. *Clin Neurol Neurosurg*. 2020;198:106236.
83. Shukla A, Hsu FC, Slobogean B, et al. Association between patient-reported outcomes and objective disease indices in people with NF2. *Neurol Clin Pract*. 2019;9(4):322–329.
84. Zamanipoor Najafabadi AH, Peeters MCM, Dirven L, et al. Impaired health-related quality of life in meningioma patients—a systematic review. *Neuro Oncol*. 2017;19(7):897–907.
85. Nassiri F, Price B, Shehab A, et al. Life after surgical resection of a meningioma: a prospective cross-sectional study evaluating health-related quality of life. *Neuro Oncol*. 2019;21(Suppl 1):i32–i43.
86. Zamanipoor Najafabadi AH, van der Meer PB, Boele FW, et al. Determinants and predictors for the long-term disease burden of intracranial meningioma patients. *J Neurooncol*. 2021;151(2):201–210.
87. Gao F, Li M, Wang Z, et al. Efficacy and safety of gamma knife radiosurgery for meningiomas in patients with neurofibromatosis type 2: a long-term follow-up single-center study. *World Neurosurg*. 2019;125:e929–e936.
88. Mohammed N, Hung YC, Xu Z, et al. Neurofibromatosis type 2-associated meningiomas: an international multicenter study of outcomes after Gamma Knife stereotactic radiosurgery. *J Neurosurg*. 2022;136(1):109–114.
89. Birkhead B, Sio TT, Pollock BE, Link MJ, Laack NN. Gamma Knife radiosurgery for neurofibromatosis type 2-associated meningiomas: a 22-year patient series. *J Neurooncol*. 2016;130(3):553–560.
90. Liu A, Kuhn EN, Lucas JT, et al. Gamma Knife radiosurgery for meningiomas in patients with neurofibromatosis Type 2. *J Neurosurg*. 2015;122(3):536–542.
91. Wentworth S, Pinn M, Bourland JD, et al. Clinical experience with radiation therapy in the management of neurofibromatosis-associated central nervous system tumors. *Int J Radiat Oncol Biol Phys*. 2009;73(1):208–213.
92. Evans DG, Halliday D, Obholzer R, et al. Radiation treatment of benign tumours in NF2-related-schwannomatosis: a national study of 266 irradiated patients showing a significant increase in malignancy/malignant progression. *Neuro-Oncol Adv*. 2023; doi:10.1093/nojnl/vdad025
93. Lisowski, D., Trömel, J., Lutyj, P. et al. Health-related quality of life and clinical outcome after radiotherapy of patients with intracranial meningioma. *Sci Rep* 12, 19730 (2022). <https://doi.org/10.1038/s41598-022-24192-8>
94. Cosetti MK, Golfinos JG, Roland JT. Quality of life (QoL) assessment in patients with neurofibromatosis type 2 (NF2). *Otolaryngol Head Neck Surg*. 2015;153(4):599–605.
95. Ferner RE, Shaw A, Evans DG, et al. Longitudinal evaluation of quality of life in 288 patients with neurofibromatosis 2. *J Neurol*. 2014;261(5):963–969.
96. Graillon T, Sanson M, Campello C, et al. Everolimus and octreotide for patients with recurrent meningioma: results from the phase II CEVOREM Trial. *Clin Cancer Res*. 2020;26(3):552–557.
97. Osorio DS, Hu J, Mitchell C, et al. Effect of lapatinib on meningioma growth in adults with neurofibromatosis type 2. *J Neurooncol*. 2018;139(3):749–755.
98. Yeung J, Yaghoobi V, Aung TN, et al. Spatially resolved and quantitative analysis of the immunological landscape in human meningiomas. *J Neuropathol Exp Neurol*. 2021;80(2):150–159.
99. Bi WL, Nayak L, Meredith DM, et al. Activity of PD-1 blockade with nivolumab among patients with recurrent atypical/anaplastic meningioma: phase II trial results. *Neuro Oncol*. 2022;24(1):101–113.
100. Tang X, Liu F, Liu Z, et al. Bioactivity and safety of B7-H3-targeted chimeric antigen receptor T cells against anaplastic meningioma. *Clin Transl Immunol*. 2020;9(6):e1137.
101. Jenkinson MD. ‘Meningiomics’—an integration of data on the patient, tumour, extent of resection and molecular pathology to optimise the management and follow-up for meningiomas. *Acta Neurochir (Wien)*. 2019;161(12):2551–2552.