



HAL
open science

Cerebellar encephalitis and peripheral neuropathy with an atypical clinical and neuroimaging signature following Covid-19 vaccine: a report of two cases Authors

Marin Sicard, Natalia Shor, Vincent Davy, Jean-Jacques Rouby, Bruno Oquendo, Thierry Maisonobe, Louis Puybasset, Stephane Lehericy, Amandine Lecarpentier, Cristiano Donadio, et al.

► To cite this version:

Marin Sicard, Natalia Shor, Vincent Davy, Jean-Jacques Rouby, Bruno Oquendo, et al.. Cerebellar encephalitis and peripheral neuropathy with an atypical clinical and neuroimaging signature following Covid-19 vaccine: a report of two cases Authors. Journal of Neurology, 2024, Online ahead of print. 10.1007/s00415-024-12390-5 . hal-04580490

HAL Id: hal-04580490

<https://hal.sorbonne-universite.fr/hal-04580490>

Submitted on 20 May 2024

HAL is a multi-disciplinary open access archive for the deposit and dissemination of scientific research documents, whether they are published or not. The documents may come from teaching and research institutions in France or abroad, or from public or private research centers.

L'archive ouverte pluridisciplinaire **HAL**, est destinée au dépôt et à la diffusion de documents scientifiques de niveau recherche, publiés ou non, émanant des établissements d'enseignement et de recherche français ou étrangers, des laboratoires publics ou privés.



Distributed under a Creative Commons Attribution - NonCommercial - NoDerivatives 4.0 International License

Cerebellar encephalitis and peripheral neuropathy with an atypical clinical and neuroimaging signature following Covid-19 vaccine: a report of two cases

Authors

Marin Sicard,¹ Natalia Shor,² Vincent Davy,³ Jean-Jacques Rouby,⁴ Bruno Oquendo,¹ Thierry Maisonobe,³ Louis Puybasset,⁴ Stephane Lehericy,^{2,5} Amandine Lecarpentier,¹ Cristiano Donadio,¹ Christel Oasi,¹ Joël Belmin,¹ Catherine Lubetzki,^{3,5} Jean-Christophe Corvol,^{3,5} David Grabli,^{3,5} Dario Saracino^{3,5,6}

Author affiliations

¹Sorbonne Université, Assistance Publique Hôpitaux de Paris, Hôpital Charles-Foix, Service de Gériatrie à Orientation Cardiologique et Neurologique, Ivry-sur-Seine, France

²Sorbonne Université, Assistance Publique Hôpitaux de Paris, Hôpital Pitié-Salpêtrière, Department of Neuroradiology, Paris, France

³Sorbonne Université, Assistance Publique Hôpitaux de Paris, Hôpital Pitié-Salpêtrière, Department of Neurology, Paris, France

⁴Sorbonne Université, GRC 29, Assistance Publique Hôpitaux de Paris (AP-HP), Hôpital Pitié-Salpêtrière, Department of Anesthesiology and Critical Care, Paris, France

⁵Sorbonne Université, Assistance Publique Hôpitaux de Paris, Paris Brain Institute – ICM, Inserm, CNRS, Hôpital Pitié-Salpêtrière, Paris, France

⁶Sorbonne Université, Assistance Publique Hôpitaux de Paris, Hôpital Pitié-Salpêtrière, Departement of Neurology, Reference Centre for Rare or Early Dementias, Paris, France

ABSTRACT

Background. Immune-mediated neurological syndromes may occur following SARS-CoV-2 infection or vaccination. Their presentation can be extremely heterogeneous and there are no established guidelines for treatment.

Methods. We report the clinical and instrumental features of two patients presenting neurological syndromes started two weeks after Covid-19 vaccine, with infection co-occurring in one case, describe their common neuroimaging profile and illustrate their response to immunosuppressive treatment.

Results. Both patients displayed simultaneous central and peripheral nervous system involvement. Cerebellar ataxia and predominantly sensory neuropathy/neuronopathy were present in one case, whereas rapidly evolving quadriparesis, sensory level, bulbar deficits and altered vigilance characterized the other. Electrophysiological studies were in favor of both central and peripheral conduction deficits. Brain MRI displayed inflammatory changes with contrast enhancement in superior cerebellar peduncles in both cases. Intrathecal IgG synthesis was present, but no known autoantibodies were found in plasma and CSF. Immunosuppressive treatments, namely plasma exchanges and high-dose corticosteroids, had a partially favorable impact, at least on central involvement.

Conclusions. We report two cases of cerebellar encephalitis following Covid-19 exposure with an atypical neuroimaging signature involving superior cerebellar peduncles. This neuroinflammatory pattern, already identified in patients exposed to SARS-CoV-2 vaccine, suggests that cerebellar encephalitis may be considered a rare but severe adverse event of RNA vaccine against Covid-19. We also provide evidence concerning the potential benefit of intensive immunosuppressive strategies in such cases.

Word count

Title: 20 words; Text: 2129 words (including abstract); number of tables: 1; number of figures: 1; number of references: 24.

Keywords

SARS-CoV-2; Covid-19; vaccination; cerebellar encephalitis; neuropathy; plasmapheresis.

Statement and Declarations

The authors have no competing interests to declare that are relevant to the content of this article.

Corresponding Author

Dr Dario Saracino, MD, PhD

Paris Brain Institute - Institut du Cerveau (ICM)

AP-HP - Hôpital Pitié-Salpêtrière, DMU Neurosciences, Département de Neurologie, 47-83 boulevard de l'Hôpital, 75013 Paris, France

Telephone: 0033 1 57 27 46 77

Email: dario.saracino@yahoo.com

INTRODUCTION

Since the outbreak of Covid-19 pandemic several studies highlighted an association of SARS-CoV-2 infection with neurological and neuropsychiatric illness[1]. While the evidence of clear neurotropism for SARS-CoV-2 is still lacking[2], para-infectious or post-infectious immune-mediated neurological complications have been documented[2–4]. As with other viral agents such as rubella or influenza viruses, infection itself or vaccination can trigger a delayed autoimmune response, probably due to viral mimicry[5]. Post-infectious/post-vaccinal Covid-19 neurological syndromes may involve both the central (CNS) and peripheral nervous system (PNS). Despite the lack of rigorous epidemiological studies[6], their incidence remained relatively low throughout Covid-19 pandemic. Clinical, laboratory and neuroimaging presentations can be highly heterogenous[7]. In most cases, no relevant autoantibodies, in particular against neural-surface antigens are found[8]. Immunosuppressive regimens (corticosteroids, plasma exchanges (PE), anti-CD20 antibodies) have been employed in such cases with variable efficacy, but there are still no consensual treatment guidelines.

Hereby we report two patients presenting neurological complications following Covid-19 exposure (vaccination in both cases, and concurrent infection in one of them) both displaying the same atypical neuroimaging profile and featuring simultaneous involvement of CNS and PNS, and we illustrate their response to immunosuppressive treatment.

CASE DESCRIPTIONS

Patient 1

The first patient, an individual in their 70s without prior remarkable medical conditions, underwent a four-shot Covid-19 vaccination protocol (two Comirnaty® doses one month apart, then two booster doses after twelve and eighteen months, respectively). Two days after the last dose the patient presented mildly symptomatic Covid-19 infection (fever, cough, nose congestion). Two weeks after the infection lower limbs weakness, asthenia, and proprioceptive ataxia were noticed. Deep tendon reflexes were brisk. SARS-CoV-2 PCR was negative at that time. The anti-S IgG titer was >40000 U/mL and the anti-N index was positive at 2.96. Brain and spinal cord MRI were unrevealing. Nerve conduction study (NCS) showed mild amplitude reduction in sensory potentials in the four limbs. The leading

hypothesis being atypical sensory Guillain-Barré syndrome, 2 g/kg intravenous immunoglobulin (IVIg) therapy was administered, without noticeable improvement.

After 10 days the patient experienced increase in balance disorders, severe muscle weakness requiring wheelchair, and urinary and pelvic incontinence. Neurological examination showed cerebellar ataxia in upper and lower limbs, Romberg sign, nystagmus and (intermittently) dysarthric speech. Muscle strength was reduced in bilateral tibialis anterior, glutei and hamstring muscles; vibratory sense was abolished in distal lower limbs. The score at the scale for the assessment and rating of ataxia (SARA) was 13. Brain MRI showed T2/Fluid Attenuated Inversion Recovery (FLAIR) hyperintensity and enlargement of the superior cerebellar peduncles with associated patchy contrast enhancement (Figure 1A). NCS confirmed the decrease in sensory potentials with only mild motor conduction impairment. Somatosensory and motor evoked potentials (EP) were in favor of both peripheral and central slowing, greater in lower limbs. Cerebrospinal fluid (CSF) analysis only displayed slightly increased proteins (0.48 g/L) and intrathecal oligoclonal IgG synthesis. Infectious workup including herpesviruses, hepatitis, influenza, HIV, syphilis, and Lyme disease was negative in blood and CSF. Testing for neuropathy/neuronopathy-associated antibodies (gangliosides, fibroblast growth factor receptor-3, neurofascin proteins 155 and 186, contactin, contactin-associated protein-1, argonaute proteins) as well as demyelinating disorders of the CNS (aquaporin-4 (AQP4), myelin oligodendrocyte glycoprotein (MOG), myelin-associated glycoprotein) was negative. In addition, screening for antibodies against extracellular and intracellular neuronal antigens using tissue-based indirect immunofluorescence assay in serum and CSF was negative. No anti-interferon-alpha antibodies were detected.

After an attempt with an IV methylprednisolone 1 g for 10 days, with limited efficacy, the patient was treated with ten PE, followed by oral steroids (prednisone 1 mg/kg for 4 weeks then slow tapering). Motor deficit and cerebellar signs significantly improved after the PE series, whereas sensory deficits and proprioceptive ataxia persisted. At six months from onset, SARA score was 6. Progressive resolution of brain lesions was observed at follow-up MRI (Figure 1B), with spinal cord MRI being persistently normal. Sensory and motor amplitudes slightly increased, with improvement in central conduction. At 21-month follow-up the patient can walk without supports, take stairs, ride a bike, though being still impaired in tandem gait and in keeping balance without visual control. NCS were overall stable, without significant recovery.

Patient 2

The second patient was an individual in their 80s with mild neurocognitive and gait disorder due to chronic adult hydrocephalus and cerebral small-vessel disease diagnosed 5 years before, who underwent a four-shot Covid-19 vaccination protocol (2 Spikevax® doses one month apart, then two Comirnaty® boosters, after 5 and 11 months). The patient presented rapidly progressive weakness and numbness in lower limbs and urinary incontinence two weeks after the last shot. Neurological examination showed flaccid paralysis of lower limbs and T10 sensory level. Spinal cord MRI was unrevealing. NCS evidenced only mild reduction in amplitude of sensory and motor potentials.

About a month after onset their conditions rapidly worsened, with extension of motor deficit also to upper extremities, mainly to distal muscle groups, and the appearance of dysarthria, hypophonia, apathy and fluctuations in vigilance. Brain MRI (Figure 1C) showed T2/FLAIR hyperintensity and enlargement of the superior cerebellar peduncles, with associated contrast enhancement. NCS found further decrease of motor potentials with conduction blocks at lower limbs. Somatosensory and motor EP were consistent with both central and peripheral conduction deficits, more severe in lower limbs. Spinal cord MRI was persistently negative. CSF analysis showed increased proteins (0.57 g/L) and intrathecal IgG synthesis. SARS-CoV-2 PCR was negative, anti-S IgG titer was 7080 U/mL and anti-N index was negative. Infectious and autoimmune testing, as in the first case, was unrevealing.

Due to the inefficacy of IV steroids and the severity of the clinical deficits, the patient underwent ten PE followed two weeks after by two administrations of Rituximab 1000 mg. The patient displayed only mild improvement, with normalization of vigilance and recovery of speech, but with no noticeable changes in limb strength. Follow-up brain MRI at 6 months (Figure 1D) showed progressive lesion reduction, whereas NCS showed slight further decrease in sensory and motor amplitudes. Clinical conditions did not change, as the patient was still bedridden without any motor recovery.

Clinical, laboratory and instrumental features of the two patients are summarized in Table 1.

Discussion

Post-covid neuroinflammatory processes have been reported before as rare complications of symptomatic SARS-CoV-2 infection or vaccination. Those syndromes can range across a

wide spectrum of clinical presentations including acute disseminated encephalomyelitis[4, 9], rhombencephalitis[10], Bickerstaff's brainstem encephalitis[11], myelitis[12], and Guillain-Barré syndrome[13]. Their pathophysiological mechanisms likely include sustained inflammatory response, trigger of immune activation and production of self-reactive antibodies[14].

In this report, we describe two cases of neurological syndromes occurring about two weeks after SARS-CoV-2 immune stimulation (Comirnaty® vaccine and mildly symptomatic infection occurring 48 hours apart in the first patient, and Comirnaty® vaccine alone in the second patient). Though it is difficult to disentangle whether viral infection or vaccination were the main trigger in the first patient, the delay is highly suggestive of post-infectious / post-vaccinal process in both cases. Accordingly, in the specific case of Covid-19 neurological sequelae, mean timeframe between symptomatic infection and onset of neurological symptoms ranges from 12 to 20 days (lowest in case of seronegative encephalitis and highest in case of ADEM)[15].

Both patients of our series displayed the same neuroimaging signature, consisting of bilateral involvement of the superior cerebellar peduncles on brain MRI. Despite symmetric appearance of SCP abnormalities, MRI findings including vasogenic oedema (T2/FLAIR and diffusion signal hyperintensity with no apparent diffusion coefficient restriction) and associated patchy gadolinium enhancement were consistent with inflammatory process. This was further supported by the presence of intrathecal IgG synthesis, and the partial response to immunosuppressive treatment. The localization of these processes correlated with cerebellar ataxia in the first case and with apathy and reduced alertness in the second one. Previous reports have highlighted unusual patterns of CNS involvement following Covid-19 infection or vaccination, different from those encountered in acute disseminated encephalomyelitis cases, and mostly localized to infratentorial structures[9, 16]. Cases presenting with Bickerstaff's encephalitis[11] and neuromyelitis optica spectrum disorder (NMOSD)[17] have been reported, in association with their defining autoantibodies. This study emphasizes the significance of bilateral involvement of the superior cerebellar peduncles. Neuroinflammatory changes in this area should not be disregarded, occurring in isolation or in association with white matter hypersignals present elsewhere, since they may represent an atypical yet consistent finding in patients manifesting neurological changes following immune stimulation, as previous works and ours point out[16, 18].

Notably, disease course was characterized by sequential development of neurological deficits in both patients, with delayed increase of functional impairment compared to disease onset, particularly in the second one. Post-infectious / post-vaccinal neurological syndromes usually follow a monophasic course, even if stepwise progression of neurological deficits is not uncommon, in particular when CNS and PNS are both involved [19]. Of interest, a unique case of recurrent ADEM following Covid-19 exposure, also featuring posterior fossa abnormalities at brain MRI, has been recently described in a patient with a likely genetic predisposition to autoimmune disease[20]. Another intriguing point concerning patient 2 was the presence of clinical and electrophysiological signs of myelopathy with persistently negative spinal cord MRI. Previous reports described cases of MRI-negative myelitis in the context of autoimmune disorders of CNS, mainly MOG-IgG-associated disorder (MOGAD), where their frequency may be as high as 10%[21]. Possible explications include the insensitivity of MRI to the detection of antibody-mediated inflammation, or a functional glial cell disturbance mediated by anti-MOG antibodies[21]. However, the research of antibodies involved in CNS demyelinating disorders turned negative in both our patients. Interestingly, a few cases of MRI-negative myelitis following Covid-19, with altered EP and evidence of intrathecal IgG synthesis, but not anti-MOG or anti-AQP4 antibodies, have been reported[22], suggesting that the yet undefined causative antibodies may share a pathophysiological mechanism like what observed in MOGAD.

Some evidence exists in favor of an overlap between Bickerstaff's encephalitis and Guillain-Barré syndrome[23] suggesting a continuum in their physiopathology. Accordingly, our two cases showed different profiles of PNS involvement co-occurring with central deficits, in the form of sensory neuropathy/neuronopathy in one case, and severe motor neuropathy/neuronopathy in the other. A previous case of NMOSD and polyradiculitis after Covid-19 infection and vaccination has been reported, with the central involvement being attributed to the vaccine and the peripheral findings to the infection[17]. Our data do not support this hypothesis: injury of the superior cerebellar peduncles was induced by vaccination alone (patient 2) or vaccination plus Covid-19 infection (patient 1). Hence, it is likely that the immune response triggered by either SARS-CoV-2 infection or vaccination may translate in CNS and PNS lesions due to antigen commonalities[23, 24]. However, this remains conjectural as no autoantibodies have been found despite multiple tests.

Finally, our study illustrates the favorable impact of intensive immunosuppressive treatments on CNS involvement. In the absence of consensual treatment guidelines, PE were chosen for

their expected efficacy and rapidity of action, after unsuccessful attempts with IV steroids. Oral steroid treatment and gradual tapering promoted clinical recovery in the first case, whereas neurological deficits persisted despite adding anti-CD20 treatment in the second case. The difference in the overall clinical outcome was possibly due to the older age and the pre-existing neurological conditions in the second patient.

In conclusion, our series highlights that inflammatory adverse events following Covid-19 exposure may simultaneously or sequentially affect both the superior cerebellar peduncles and the peripheral nervous system and may be reversed by intensive immunosuppressive treatments. Our cases and the previously reported ones suggest that cerebellar encephalitis with signal changes in superior cerebellar peduncles may be considered a rare but severe adverse event of RNA vaccine against Covid-19.

Declarations

Funding

The authors did not receive support from any organization for the submitted work.

Competing Interests

The authors have no competing interests to declare that are relevant to the content of this article.

Ethics Approval

All procedures performed in studies involving human participants were in accordance with the ethical standards of the institutional and/or national research committee and with the 1964 Helsinki Declaration and its later amendments or comparable ethical standards.

Consent

Informed consent for data reporting and publication was obtained from all individual participants included in the study.

CRedit Author Statement

Conceptualization : Dario Saracino, Vincent Davy, David Grabli, Jean-Jacques Rouby;
Formal analysis and investigation: Marin Sicard, Natalia Shor, Dario Saracino; Methodology
and Software: Natalia Shor, Louis Puybasset, Stéphane Lehéricy; Resources: Natalia Shor,
Vincent Davy, Bruno Oquendo, Thierry Maisonobe, Amandine Lecarpentier, Cristiano
Donadio, Christel Oasi, Joël Belmin; Writing - original draft preparation: Marin Sicard, Dario
Saracino; Writing - review and editing: Natalia Shor, Vincent Davy, Jean-Jacques Rouby,
Bruno Oquendo, Thierry Maisonobe, Louis Puybasset, Stéphane Lehéricy, Amandine
Lecarpentier, Cristiano Donadio, Christel Oasi, Joël Belmin, Catherine Lubetzki, Jean-
Christophe Corvol, David Grabli; Supervision: Dario Saracino.

References

1. Paterson RW, Brown RL, Benjamin L, et al (2020) The emerging spectrum of COVID-19 neurology: clinical, radiological and laboratory findings. *Brain* 143:3104–3120. <https://doi.org/10.1093/brain/awaa240>
2. Lebrun L, Absil L, Rimmelink M, et al (2023) SARS-Cov-2 infection and neuropathological findings: a report of 18 cases and review of the literature. *Acta Neuropathol Commun* 11:78. <https://doi.org/10.1186/s40478-023-01566-1>
3. Guilmot A, Maldonado Sloopjes S, Sellimi A, et al (2021) Immune-mediated neurological syndromes in SARS-CoV-2-infected patients. *J Neurol* 268:751–757. <https://doi.org/10.1007/s00415-020-10108-x>
4. Gao J-J, Tseng H-P, Lin C-L, et al (2022) Acute encephalitis after COVID-19 vaccination: A case report and literature review. *Hum Vaccines Immunother* 0:2082206. <https://doi.org/10.1080/21645515.2022.2082206>
5. Rojas M, Restrepo-Jiménez P, Monsalve DM, et al (2018) Molecular mimicry and autoimmunity. *J Autoimmun* 95:100–123. <https://doi.org/10.1016/j.jaut.2018.10.012>
6. Nabizadeh F, Noori M, Rahmani S, Hosseini H (2023) Acute disseminated encephalomyelitis (ADEM) following COVID-19 vaccination: A systematic review. *J Clin Neurosci Off J Neurosurg Soc Australas* 111:57–70. <https://doi.org/10.1016/j.jocn.2023.03.008>
7. Samim MM, Dhar D, Goyal S, et al (2022) AI-CoV Study: Autoimmune Encephalitis Associated With COVID-19 and Its Vaccines-A Systematic Review. *J Clin Neurol Seoul Korea* 18:692–710. <https://doi.org/10.3988/jcn.2022.18.6.692>
8. Ariño H, Ruiz García R, Rioseras B, et al (2023) Frequency and Referral Patterns of Neural Antibody Studies During the COVID-19 Pandemic. *Neurol Neuroimmunol Neuroinflammation* 10:e200129. <https://doi.org/10.1212/NXI.0000000000200129>
9. Parsons T, Banks S, Bae C, et al (2020) COVID-19-associated acute disseminated encephalomyelitis (ADEM). *J Neurol* 267:2799–2802. <https://doi.org/10.1007/s00415-020-09951-9>
10. Jeanneret V, Winkel D, Risman A, et al (2021) Post-infectious rhombencephalitis after coronavirus-19 infection: A case report and literature review. *J Neuroimmunol* 357:577623. <https://doi.org/10.1016/j.jneuroim.2021.577623>
11. Llorente Ayuso L, Torres Rubio P, Beijinho do Rosário RF, et al (2021) Bickerstaff encephalitis after COVID-19. *J Neurol* 268:2035–2037. <https://doi.org/10.1007/s00415-020-10201-1>
12. Mahajan A, Nayak MK, Gaikwad SB, et al (2023) Post-Vaccination/Post-COVID Immune-Mediated Demyelination of the Brain and Spinal Cord: A Novel Neuroimaging Finding. *Neurol India* 71:86–91. <https://doi.org/10.4103/0028-3886.370449>
13. Chun JY, Park S, Jung J, et al (2022) Guillain-Barré syndrome after vaccination against COVID-19. *Lancet Neurol* 21:117–119. [https://doi.org/10.1016/S1474-4422\(21\)00416-6](https://doi.org/10.1016/S1474-4422(21)00416-6)

14. Alexopoulos H, Magira E, Bitzogli K, et al (2020) Anti-SARS-CoV-2 antibodies in the CSF, blood-brain barrier dysfunction, and neurological outcome: Studies in 8 stuporous and comatose patients. *Neurol Neuroimmunol Neuroinflammation* 7:e893. <https://doi.org/10.1212/NXI.0000000000000893>
15. Ariño H, Heartshorne R, Michael BD, et al (2022) Neuroimmune disorders in COVID-19. *J Neurol* 269:2827–2839. <https://doi.org/10.1007/s00415-022-11050-w>
16. Vogrig A, Janes F, Gigli GL, et al (2021) Acute disseminated encephalomyelitis after SARS-CoV-2 vaccination. *Clin Neurol Neurosurg* 208:106839. <https://doi.org/10.1016/j.clineuro.2021.106839>
17. Kim Y, Heo D, Choi M, Lee J-M (2022) A Case Presenting with Neuromyelitis Optica Spectrum Disorder and Infectious Polyradiculitis Following BNT162b2 Vaccination and COVID-19. *Vaccines* 10:1028. <https://doi.org/10.3390/vaccines10071028>
18. Vogrig A, Tartaglia S, Dentoni M, et al (2024) Central nervous system immune-related disorders after SARS-CoV-2 vaccination: a multicenter study. *Front Immunol* 15:1344184. <https://doi.org/10.3389/fimmu.2024.1344184>
19. Marchioni E, Ravaglia S, Montomoli C, et al (2013) Postinfectious neurologic syndromes: a prospective cohort study. *Neurology* 80:882–889. <https://doi.org/10.1212/WNL.0b013e3182840b95>
20. Poli K, Kowarik M, Hamprecht K, et al (2023) Recurrent Acute Disseminated Encephalomyelitis (ADEM) after COVID-19-vaccination and after subsequent COVID-19-infection: A case report (part II). *Front Neurol* 14:1149612. <https://doi.org/10.3389/fneur.2023.1149612>
21. Sechi E, Krecke KN, Pittock SJ, et al (2021) Frequency and Characteristics of MRI-Negative Myelitis Associated with MOG Autoantibodies. *Mult Scler Houndmills Basingstoke Engl* 27:303–308. <https://doi.org/10.1177/1352458520907900>
22. Kawama K, Shimazaki R, Sunami Y, et al (2023) Case report: MRI-negative myelitis following COVID-19 with SEP abnormalities: a case series and literature review. *Front Neurol* 14:1275696. <https://doi.org/10.3389/fneur.2023.1275696>
23. Odaka M, Yuki N, Yamada M, et al (2003) Bickerstaff's brainstem encephalitis: clinical features of 62 cases and a subgroup associated with Guillain-Barré syndrome. *Brain J Neurol* 126:2279–2290. <https://doi.org/10.1093/brain/awg233>
24. Kuwabara S, Misawa S, Mori M (2013) Bickerstaff brainstem encephalitis: more common than we think? *J Neurol Neurosurg Psychiatry* 84:1184–1184. <https://doi.org/10.1136/jnnp-2013-305239>

Tables

	Patient 1	Patient 2
PNS involvement	Sensory > motor neuropathy	Flaccid paralysis
CNS involvement	Cerebellar ataxia	Quadriparesis, sensory level, speech impairment, apathy, fluctuating vigilance
MRI	T2/FLAIR hyperintensities and contrast enhancement in brainstem and SCP	T2/FLAIR hyperintensities and contrast enhancement in brainstem and SCP
NCS	Reduced amplitude of sensory > motor potentials, no conduction blocks	Severely decreased motor amplitudes with conduction blocks, reduced sensory potentials
CSF	Slightly increased proteins (0.48 g/L) Intrathecal IgG synthesis	Increased proteins (0.57 g/L) Intrathecal IgG synthesis
Antibody testing	Negative	Negative
Treatment	IVIg, IV methylprednisolone, oral corticosteroids, PE	IV methylprednisolone, PE, anti-CD20 (Rituximab)
Clinical evolution	Improvement of cerebellar syndrome, persistence of sensory deficits	Limited improvement of CNS deficits
Follow-up MRI (6 months)	Reduction of SCP volume and contrast enhancement	Reduction of SCP volume and contrast enhancement
Follow-up NCS (6 months)	Slight recovery of motor amplitudes, stable sensory conduction	Worsening of motor and sensory conduction

Table 1. Summary of clinical and instrumental findings of the two patients. CNS: central nervous system; CSF: cerebrospinal fluid; FLAIR: fluid-attenuated inversion recovery; IVIg: intravenous immunoglobulins; MRI: magnetic resonance imaging; NCS: nerve conduction study; PE: plasma exchanges; PNS: peripheral nervous system; SCP: superior cerebellar peduncle.

Figures

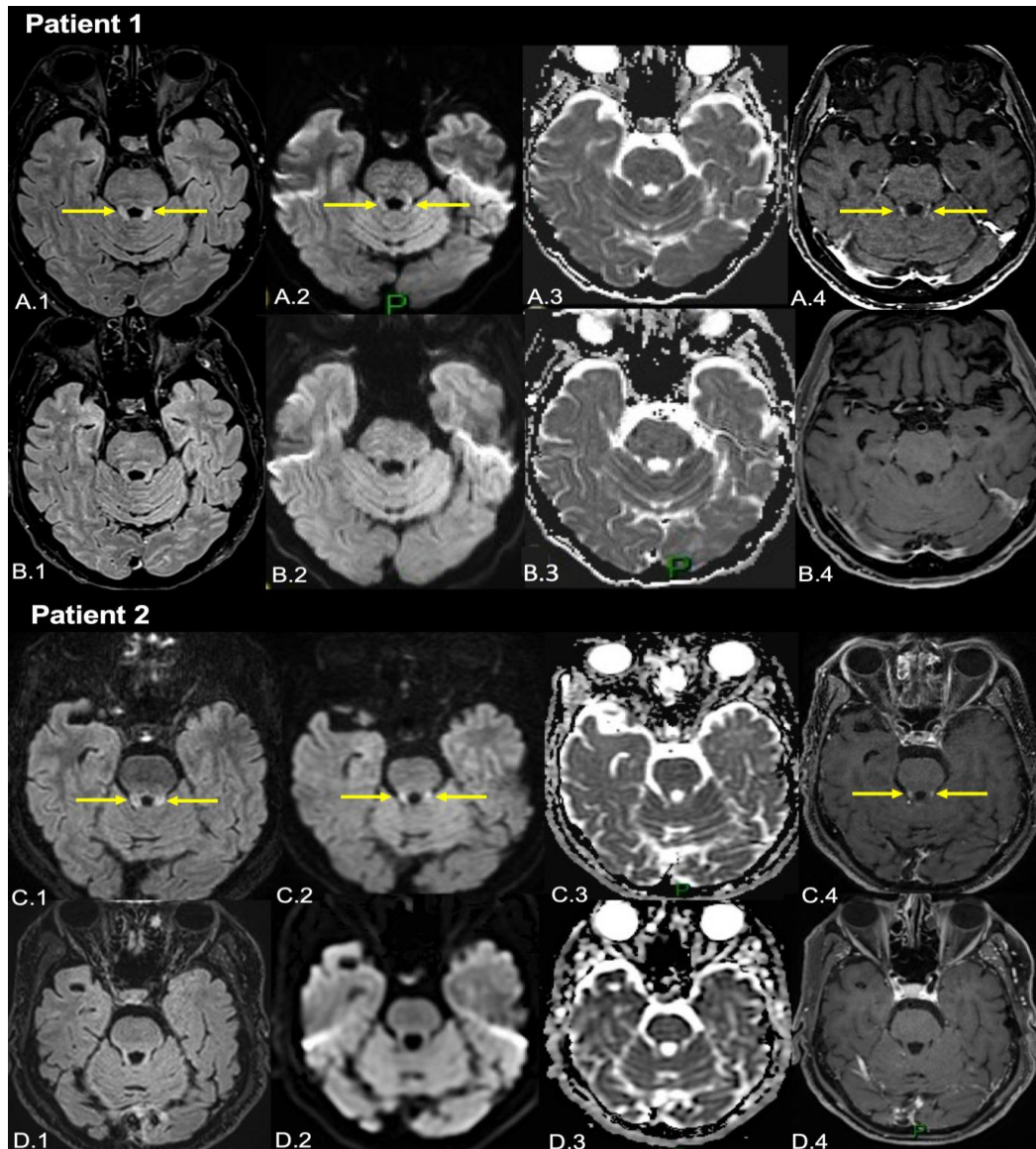


Figure 1. Brain MRI scans of the two patients. Baseline (A) and six-month follow-up (B) brain MRI of the first patient demonstrating bilateral superior cerebellar peduncles fluid attenuated inversion recovery (FLAIR) (A.1, arrows) and diffusion-weighted imaging (DWI) (A.2, arrows) hyperintensity without apparent diffusion coefficient restriction (ADC) (A.3), and with associated gadolinium enhancement on T1-weighted image (A.4, arrows). Corresponding follow-up images (B.1-4) reveal the complete disappearance of the preexisting abnormalities. Baseline (C) and six-month follow-up (D) brain MRI of the second patient with FLAIR (C-D.1), DWI (C-D.2), ADC (C-D.3) and T1-weighted post-gadolinium (C-D.4) images showing very similar initial presentation with FLAIR (C.1, arrows) and diffusion (C.2, arrows) signal hyperintensity and gadolinium enhancement (C.4, arrows) of the superior cerebellar peduncles and subsequent abnormalities disappearance.